

Quiz: Electrocardiogram

This fragment of the electrocardiogram (ECG) was recorded on the 12 leads Holter monitor (Fig. 1):.

Woman, 46 years, complains of episodes of weakness, feeling of heat in the face, palpitations and tachycardia. Sometimes these symptoms make her wake up at night.

On the day, when Holter monitoring was performed she went to bed near 22:45 and woke up at 23:41 because of recurrence of the symptoms mentioned above.

At 23:49 following ECG was recorded (Fig. 1):
How provided ECG changes can be described?

Mykhaylo Sorokivskyy,
Lviv Regional Cardiology Center,
Danylo Halytsky Lviv National Medical University,
Lviv, Ukraine

Peer-review: Internal

Authorship: M.S.

Conflict of interest: None to declare

Acknowledgement and funding: None to declare

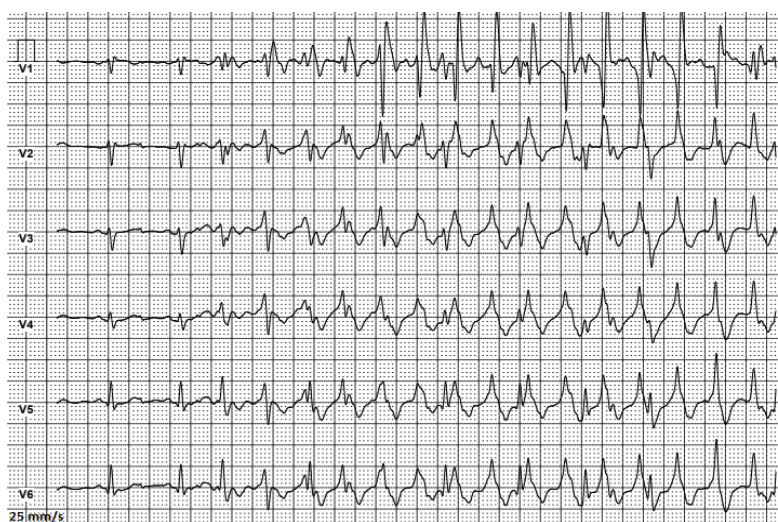
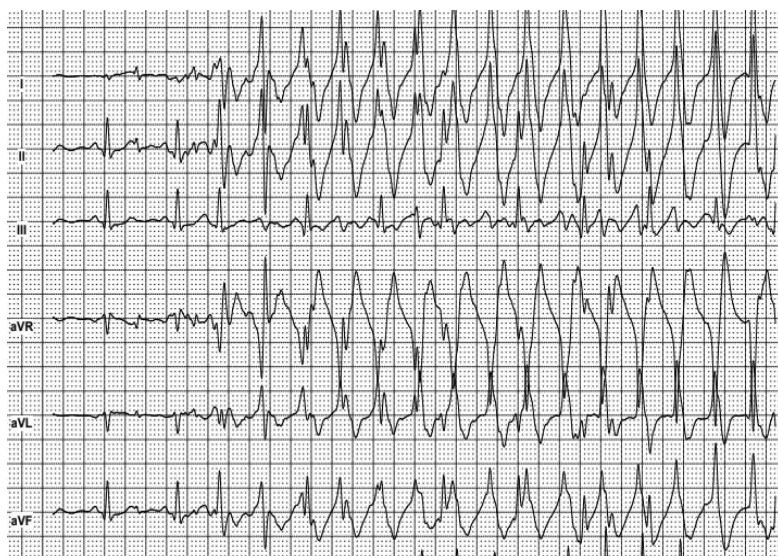


Figure 1. ECG 1
ECG –electrocardiogram

Address for Correspondence: Mykhaylo Sorokivskyy, Lviv Regional Cardiology Center, Danylo Halytsky Lviv National Medical University, Lviv, Ukraine

Email: msorokivskyy1@gmail.com

Received: 13.02.2019 **Accepted:** 14.02.2019

Copyright ©Heart, Vessels and Transplantation, doi: 10.24969/hvt.2019.106