

Quiz: Electrophysiology

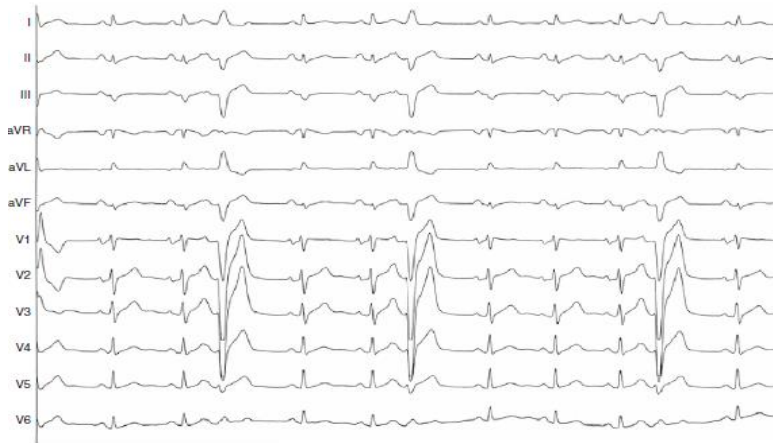

Figure 1. Twelve-lead ECG. Sinus rhythm and short coupling atrial ectopies (with functional left bundle branch block [LBBB])

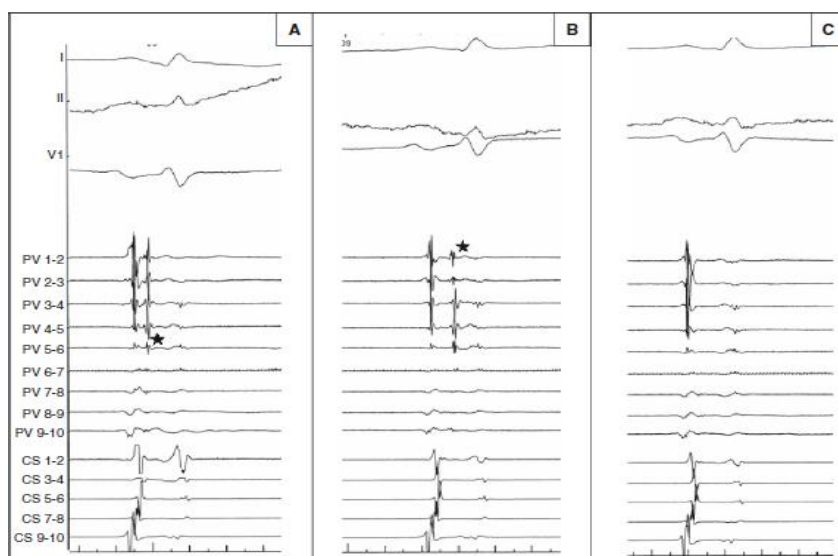


Figure 2. A decapolar catheter was inserted inside the coronary sinus (CS) while the ablation catheter and a decapolar circumferential catheter (Lasso) were introduced through a long sheath in the left atrium (LA). The circumferential catheter was placed in the left superior pulmonary vein (LSPV) and recorded venous and atrial potentials

What mechanism is illustrated (Fig. 1) and what action is required?

- A. Ectopic rhythm from the ostium of the pulmonary veins, Isolation of the pulmonary veins
- B. Premature beat from RV, RFA of ventricular ectopy
- C. Fascicular premature beat, RFA of the distal part of RBBB
- D. Ectopic rhythm from the roof of the left atrium, linear ablation on the roof of the left atrium

Ayan Abdrakhmanov, Zhandos Esilbayev
Department of Interventional Arrhythmology
National Research Cardiac Surgery Center
Astana, Kazakhstan

Peer-review: Internal

Authorship: A.A. and Z.E. equally contributed to preparation of quiz

Conflict of interest: None to declare

Acknowledgement and funding: None to declare

Address for Correspondence: Ayan Abdrakhmanov, Department of Interventional Arrhythmology, National Research Cardiac Surgery Center Astana, Kazakhstan, Email: ayan-3@mail.ru

Received 24.01.2019 **Accepted:** 25.01.2019

Copyright © 2019 Heart, Vessels and Transplantation

doi: 10.24969/hvt.2019.111