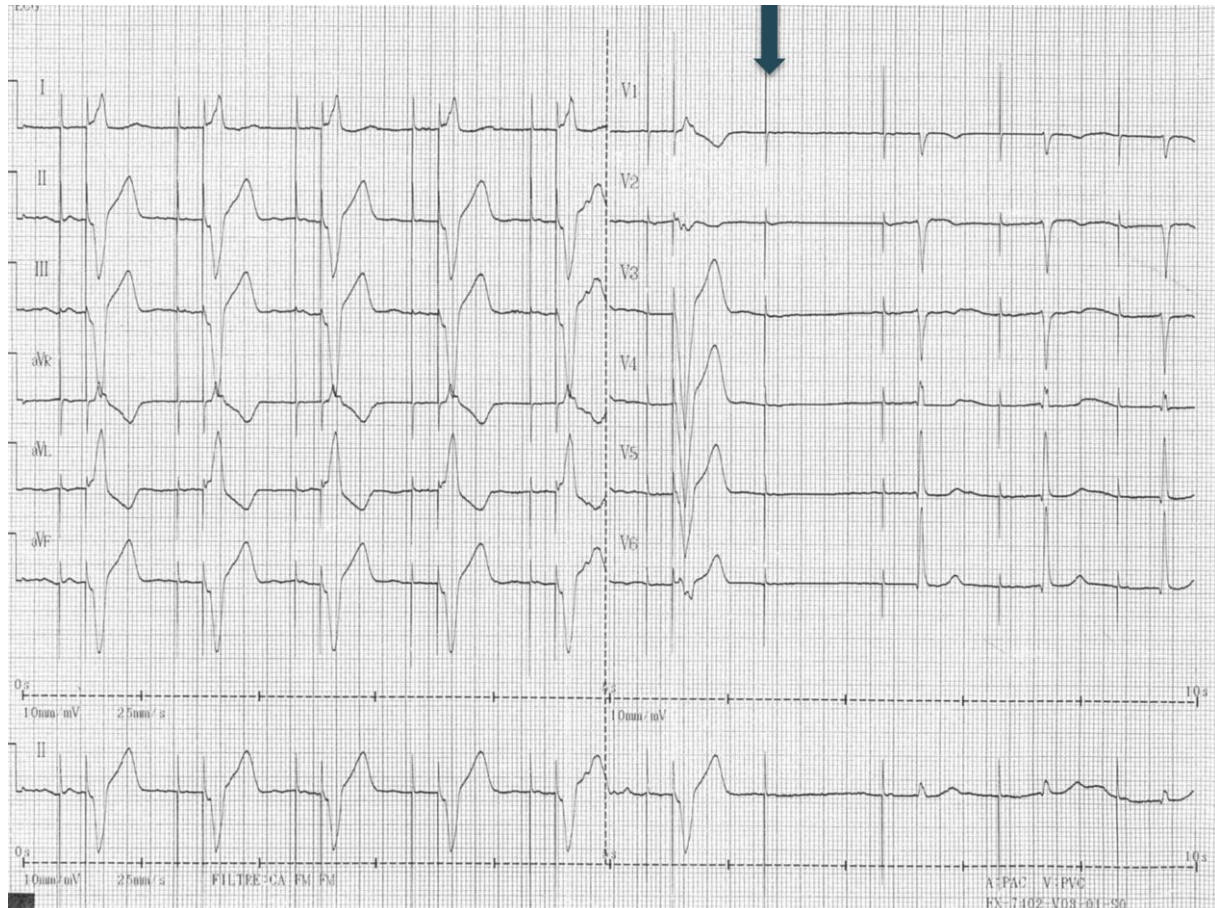


## QUIZ: Pacemaker

### Presentation

A routine follow-up twelve-lead ECG (Fig. 1) is performed in a 70 years old male patient implanted with a dual-chamber

pacemaker for sick sinus syndrome two years ago (Model Reply DR, Sorin). The patient is strictly asymptomatic.



**Figure 1. Electrocardiogram tracing**

**What is the most likely explanation for the 7th beat ?**

- 1/ There is an intermittent ventricular pacing dysfunction.
- 2/ There is an intermittent atrial pacing dysfunction.
- 3/ There is no dysfunction.
- 4/ There may be some noise on the ventricular lead.

Sok-Sithikun Bun, Karim Hasni  
Cardiology Department,  
Princess Grace Hospital, Monaco

**Peer-review:** internal

**Conflict of interest:** None to declare

**Authorship:** S.S.B. and K.H. equally  
contributed to preparation of quiz

**Acknowledgement and funding:** None to  
declare

**Address for Correspondence:** Sok-Sithikun Bun, Cardiology Department, Princess Grace Hospital, Monaco  
Email : [sithi.bun@gmail.com](mailto:sithi.bun@gmail.com) Phone : +377 97 98 97 71 – Fax : + 377 97 98 97 32

**Received:** 23.03.2019 **Accepted:** 24.03.2019

**Copyright© 2019 Heart, Vessels and Transplantation**