

Quiz: Electrocardiogram

Presentation

Female, 78 years old, complains on weakness, dizziness, loss of consciousness several times during last week.

Fragment of electrocardiogram (ECG) was recorded using 3 leads Holter monitor at the evening during the rest (Fig.1.).

Speed of the recording – 25 mm/s.

The correct description of this ECG is:

- A) Atrioventricular (AV) block I degree
- B) AV block II degree, Wenckebach
- C) AV block II degree, 2:1
- D) AV block II degree, Mobitz
- E) AV block II degree, advanced
- F) AV block III degree, complete

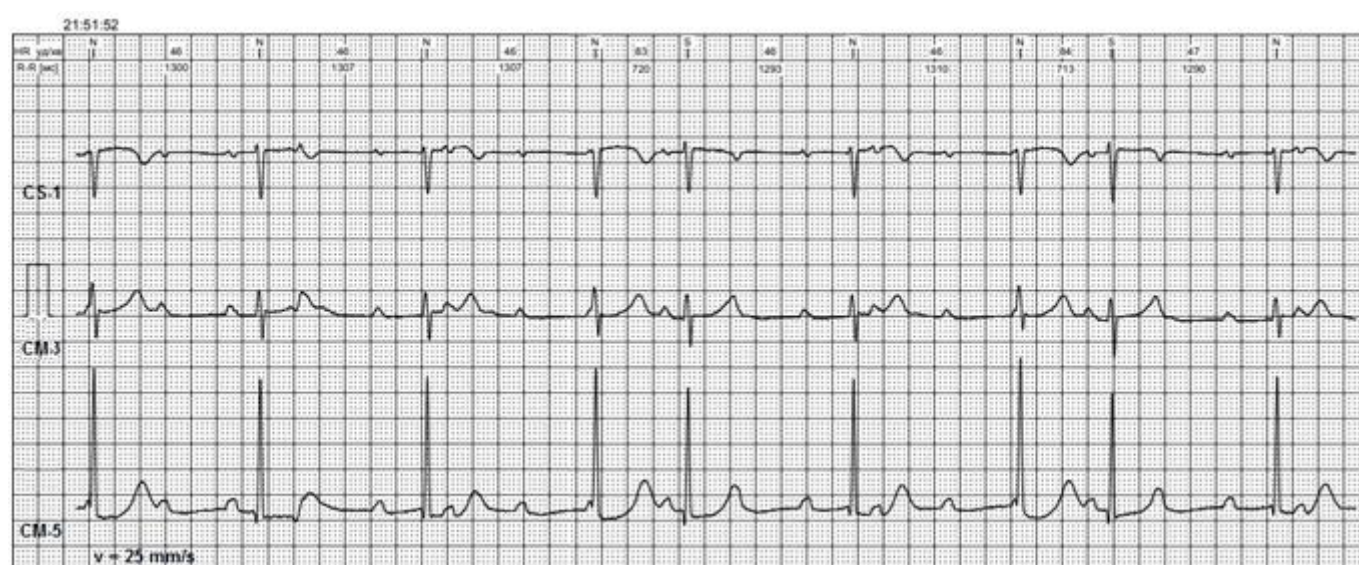


Figure1. Fragment of the 3-channel Holter monitoring

Mykhaylo Sorokivskyy, Ulyana Chernyaha-Royko
Danylo Halytsky Lviv National Medical University,
Lviv Regional Cardiology Center, Lviv, Ukraine

Peer-review: internal

Conflict of interest: None to declare

Authorship: M.S. and U.C-R. equally contributed to preparation of quiz

Acknowledgement and funding: None to declare

Address for Correspondence: Mykhaylo Sorokivskyy, Danylo Halytsky Lviv National Medical University,
Lviv Regional Cardiology Center, Lviv, Ukraine; Email: msorokivskyy1@gmail.com

Received: 14.10.2019 **Accepted:** 15.10.2019

Copyright© 2019 Heart, Vessels and Transplantation

doi: 10.24969/hvt.2019.161