

Role of multidetector computed tomography in the selection of the optimal surgical approach for the aortic valve replacement

Azat K. Turgunov, Taalaibek Z. Kudaiberdiev

SRI of Heart Surgery and Organ Transplantation, Bishkek, Kyrgyzstan

Abstract

More than 100 years have passed since the first successful operation on the aortic valve by expanding the stenotic aortic valve through the invaginated aortic wall by A. Taffer in 1914. Since then, medicine has been continuously developing, revealing new methods not only of diagnosis, but also of surgical treatment. One of these cases is, the role of multidetector computed tomography in the selection of the optimal surgical approach to replacing the aortic valve. We present here a review of current evidence on topic.

Key words: multidetector computed tomography, minimally invasive surgery, aortic valve replacement, outcomes, surgical procedures

(Heart Vessels Transplant 2022; 6: 22-7. doi :10.24969/hvt.2022.313)

Introduction

The relevance of this topic is due to the fact that in the structure of cardiovascular diseases, acquired defects account for up to 25% and are second only to coronary heart disease and hypertension in prevalence (1, 2). There are many acquired heart defects, and a special place is occupied by aortic valve defects, among which calcinated aortic stenosis (AS) is the most common organic lesion of the heart valves found in cardiology practice, which accounts for approximately 25% of all valvular heart diseases. The incidence of this defect in the general population is steadily increasing: in persons older than 65 years - 3-4%, in patients 80 years and older - 7-8% (degenerative, senile aortic stenosis) (3, 4).

Currently, surgical treatment of aortic heart defects includes replacement of valve with an artificial prosthesis. The technique of aortic valve replacement (AVR) has already become a proven, routine procedure performed by accessing the heart through a longitudinal median sternotomy, which is recognized as the "gold standard" in all cardiac surgeries (5,6).

Despite the obvious advantages of longitudinal median sternotomy as access to the heart, in-depth studies in recent years have made it possible to report potential disadvantages

of access associated with high invasiveness, the risk of bleeding (7), the development of superficial soft tissue infections and mediastinitis (8), when postoperative mortality reaches up to 50% (6).

Taking in account disadvantages of longitudinal median sternotomy and as the technology of heart surgery improved, cardiac surgeons sought out and developed new surgical techniques that would provide less traumatic operations that exclude longitudinal median sternotomy. Thus, cardiac surgery has changed its direction in the direction of reducing invasiveness (9).

Mini invasive AVR (mini-AVR) was proposed by Cosgrove and Sabik in 1996 (10). Over time, the upper partial (j-shaped) sternotomy has become the most common used technique. (Fig. 1) (11). The accumulation of experience and positive results of interventions have created the conditions for the widespread adaptation of mini-AVR (port access). However, the mini-AVR remains a rare operation, most commonly is performed in Germany – 25%. In the United Kingdom and the United States, only 12% of interventions were performed using mini-access (12).

However, some studies have shown that smaller incisions lead

Address for Correspondence: Azat K. Turgunov, SRI of Heart Surgery and Organ Transplantation, Bishkek, Kyrgyzstan
Email: azatturgunov@gmail.com

Received: 10.08.2022 **Revised:** 08.01.2022, 02.03.2022 **Accepted:** 03.03.2022

Copyright ©2022 Heart, Vessels and Transplantation

to poor visibility, potentially making surgery more complex and dangerous, as well as increasing the time of surgery (13).

Imaging for optimal surgical access

Currently, the use of modern diagnostic methods to prepare the patient for surgery, such as multidetector computed

tomography (MDCT), is the most informative in solving the issue of optimal surgical access.

Rapid technical improvement of MDCT has significantly expanded the possibilities of non-invasive diagnosis of heart and coronary artery diseases.

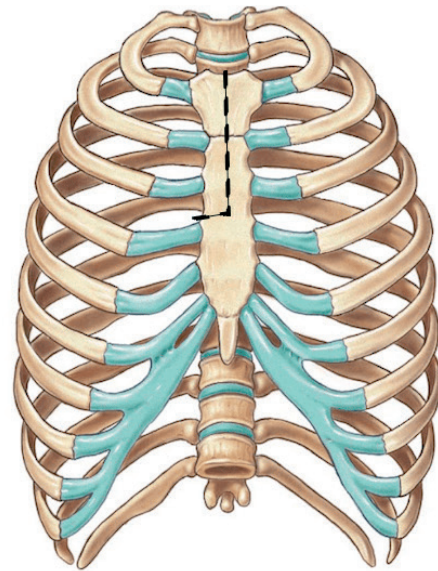
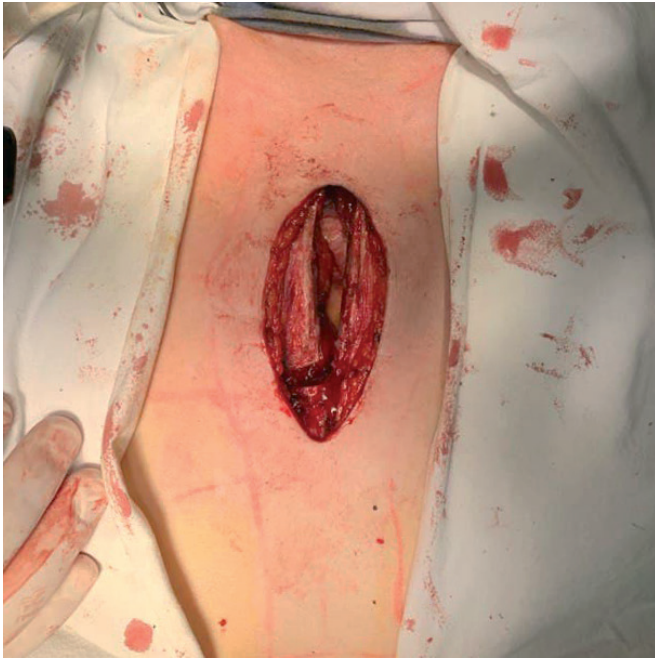


Figure 1. "J" mini sternotomy, minimally invasive aortic valve replacement

The appearance of MDCT systems with 64, 256 and 320 rows of detectors has significantly improved the quality of the images, which makes it possible to assess not only the lumen of the coronary arteries, the condition of the heart cavities and the thickness of the wall, but also to analyze the functions of the chambers, to identify pathological changes in the valves and their location in relation to the sternum (14).

According to MDCT, the clear boundaries of the heart are already known, which are located in the lower front part of the mediastinum, to the left of the median plane by an average of 13.8 (0.9) mm. Transverse dimensions prevail over the anterior and posterior - 100.9 (0.6) mm and 105.1 (1.7) mm, respectively. In relation to the sternum, the heart is located at 7.0 (0.5) mm; relative to the spine - 22.1 (1.0) mm. Heart cavities, as well as partitions between individual chambers, as a rule, can be detected only with bolus contrast. This is due to the fact that the density of blood in the chambers of the heart is approximately equal to the density of the myocardium. The outer contour of the heart is formed by the pericardium and a strip of epicardial fat. The pericardium attaches to large vessels at the level of the aortic arch, forming a kind of "bag", the contents of which are the

heart, adipose tissue and parts of large vessels emanating from the heart or flowing into it (15).

To determine optimal surgical access, the most important is to obtain dynamic computed tomography angiography images at 70% of the cardiac cycle (mid-diastole) because in this phase the aortic valve is closed (16). The access distance and the angle of access are determined on the basis of the location of three landmarks: the center of the aortic ring, the sinotubular junction and the incision site (periosteal joint) (Fig. 2, 3) (17).

Glauber et al. (18) stated that patients are suitable for minithoracotomy only if the following criteria are met: 1. the distance from the ascending aorta to the sternum should not exceed 10 cm; 2. the angle between the midline of the sternum and the slope of the ascending aorta should be greater than 45°. It has also been suggested that it is important to measure the size of the aortic valve, such as the diameter of the aortic valve ring, the length of the ascending aorta, and the calcification of the aortic valve and ascending aorta during the planning process before the procedure, as this is very important. It is recommended to remove all eccentric calcifications and create a complete decalcification of the aortic ring (18, 19).

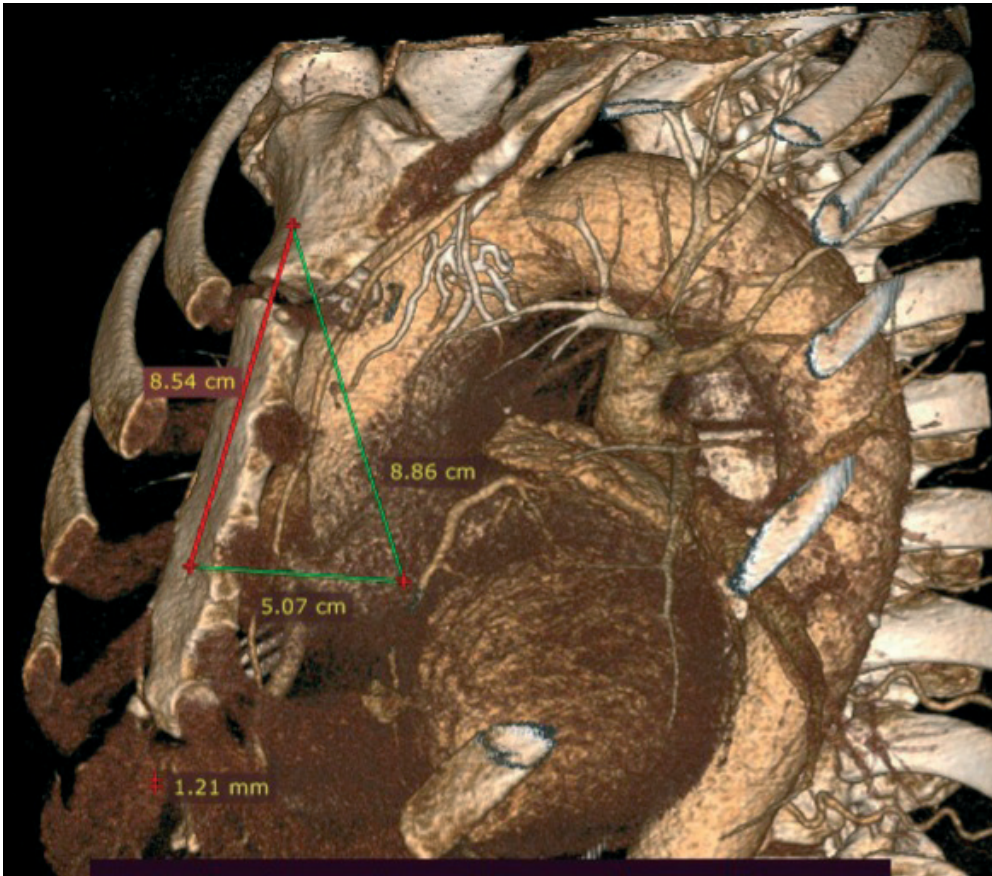


Figure 2. Contrast-enhanced multidetector computed tomography. Mid-clavicular line. Access distance and angle of access are determined based on the location of three landmarks: the center of aortic annulus, the sinotubular junction, and the incision site: 8.54 cm is the proposed skin incision line (2cm below the jugular notch, up to the 4th intercostal space)

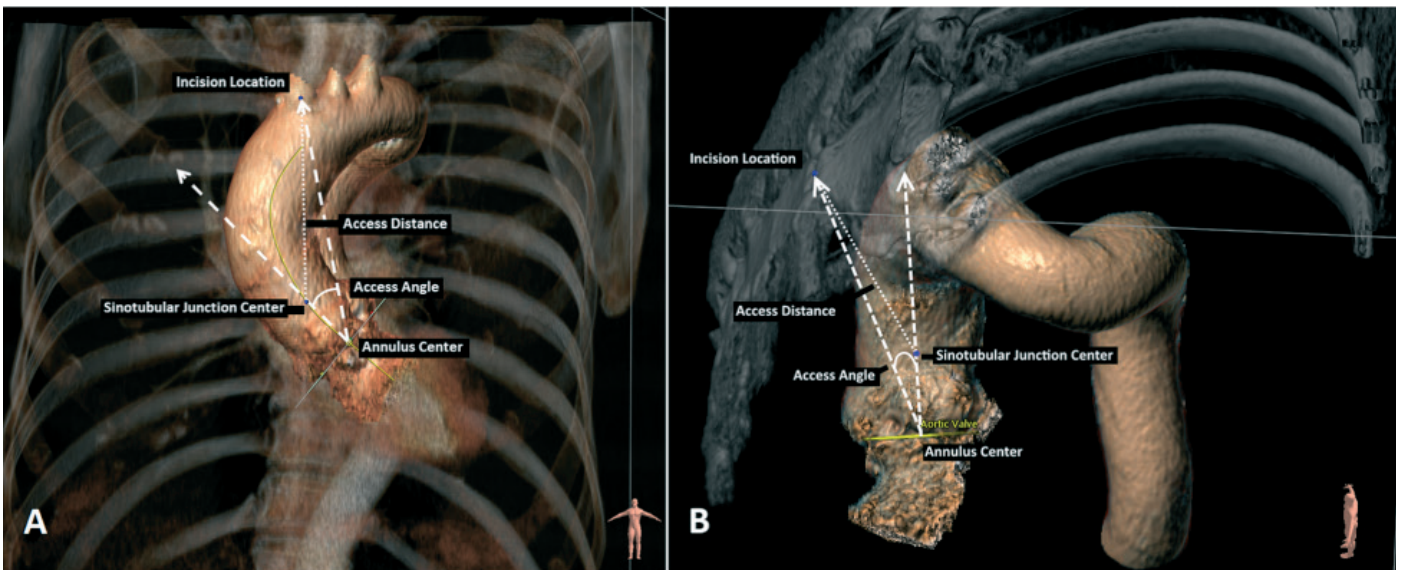


Figure 3. Anterior (surgical) view of the aorta and chest. B) Latero-superior projection of the aorta and part of the thorax. Access distance and angle of access are determined based on the location of three landmarks: the center of the aortic annulus, the sinotubular junction, and the incision site (arm-thoracic joint) (Reproduced from ref 17. Copyright 2019; under CC-BY 4.0 license)

Table 1. Outcomes of minimal invasive AVR

Study	Type of AVR	Preoperative characteristics			Operative characteristics			Postoperative outcomes		
		Male, n	NYHA	Age, years	Duration of surgery, min	Cross-clamp time, min	CPB time, min	Hospital, days	Packed red blood cells, units	Resternotomy for major bleeding
Henryk et al. 2018 ²⁰	Full-AVR 126 patients	51	3.0 (1.0)	70.02 (10.51)	198.46 (47.21)	70.01 (18.96)	108.52 (32.77)	11	1.75 (2.73)	4
	Mini-AVR 91 patients	69	3.0 (1.0)	69.79 (10.38)	194.13 (37.47)	76.43 (18.85)	107.46 (24.02)	10	0.88 (1.35)	3
Snegirev et al. 2019 ²⁶	Full-AVR 56 patients	31	3.0 (1.0)	61.5 (11.3)	173.2 (3.3)	62.0 (14.0)	85.1 (20.9)	7.7(2.2)	2.5(1.5)	2
	Mini-AVR 66 patients	69	3.0 (1.0)	64.6 (11.6)	206.0(47.9)	84.9(23.4)	117.9 (30.4)	7.4(2.7)	2.0(1.3)	3

Multi-detector computed tomography guided AVR

Study	Patients	Female, n(%)	NYHA class \geq III, n(%)	Age	Mean (standard deviation)			β -coefficient (95 CI%)		
					Annulus minimum diameter (mm)	Annulus maximum diameter (mm)	Annulus area (mm ²)	Calcium volume (mm ³)	Distance from incision (mm)	Access angle (degrees)
Boti et al. 2019 ¹⁷	100	34 (34)	16 (16)	71 (63, 75)	23.8 (3.3)	29.1 (4.1)	$5.5 \cdot 10^2$ ($1.8 \cdot 10^2$)	0.008 (0.000, 0.016)	0.074 (-0.28, 0.43)	-0.090 (-0.50, 0.32)

Planning tool mini-AVR provides both distance and angle of access from potential incision sites to the aortic root based on the geometric location of the landmarks of the aortic root and incision sites (19). These parameters are defined as follows: the access distance is defined as the distance between the location of the incision in the breast bone and the sinotubular junction of the aorta as for ministerial, and for traditional approaches. The access angle is defined as the angle between the centerline of the aortic root and the incision-ring line. Central axis of the aortic root it is a vector connecting the centers of the ring and sinotubular connection. The central axis of the cut-ring is a vector that connects the incision to the center of the ring. Other dimensions of the ring space, such as minimum, maximum diameters, area, perimeter and the volume of calcium are calculated on the basis of the previously presented automated method, which automatically determines the landmarks of the aortic root and calculates the size parameters (19). Some parameters are shown in Table 1.

Outcomes of mini-AVR

Claims to reduce postoperative complications, length of stay, and mortality were based on studies comparing traditional aortic valve surgery with minimally invasive techniques (20). Small incisions in minimally invasive surgery (Fig. 1) have the proposed advantage of less surgical trauma resulting in less

postoperative bleeding, fewer blood transfusions, and a lower incidence of deep wound infections of the sternum (21-24).

In addition, patients tend to experience less pain and faster postoperative recovery, along with improved cosmetic outcomes, leading to faster recovery and a faster return to normal activities (25).

Finally, avoiding the use of partial sternotomy theoretically allows for a safer re-entry in the event of a second operation. Therefore, many people believe that minimally invasive aortic valve prostheses have become an effective treatment option in experienced centers, providing greater patient satisfaction and a lower complication rate (16, 26).

According to a study by Henryk et al. (14) (Table 1), where 126 patients underwent mini-AVR and 91 patients had complete AVR, mini-AVR was associated with a decrease in ventilation time (6 h (3-76h) versus 8 h (3-240h); $p = 0.004$), shorter stay in intensive care unit (ICU) (2 days (1-25) versus 4 days (1-35); $p = 0.031$) and reduced transfusion requirements (26.5% vs. 56.0%; $p = 0.004$). Total length of hospital stay as well as postoperative pain levels were comparable (14).

In a study by Snegirev et al. (24) ministernotomy was accompanied by longer cardiopulmonary bypass and aortic cross-clamp times, but did not affect mortality, however

there were less bleeding and less transfusion requirement in ministernotomy group.

Conclusion

As a result of reviewing and studying the studies, it can be concluded that the replacement of the aortic valve with minimally invasive methods is more effective. The data obtained on the use of multidetector computed tomography will make it possible to determine the optimal surgical access as accurately as possible. This will reduce the intraoperative time, the duration of artificial circulation and postoperative complications. It should be noted that the postoperative condition of the patient, the fastest recovery, the reduction of physical limitations and pain syndrome also play a significant role in treatment.

Peer-review: Internal

Conflict of interest: None to declare

Authorship: A.K.T., T.Z.K. contributed equally to the preparation of manuscript

Acknowledgement and Funding: None to declare

References

- Taden JD, Nkomo VT, Enriquez Sarano M. Global burden of aortic stenosis. *Prog Cardiovasc Dis* 2014; 56: 565–71.
- Benjamin EJ, Blaha MD, Chiuve SE, Cushman M, Das SR, Deo R, et al. Heart disease and stroke statistics 2017. Update: a report of the American Heart Association. *Circulation* 2017; 135: e146 - e603.
- Bokeria LA. Minimally invasive heart surgery. Moscow. 1998.
- Miwa K, Takamori S, Mitsuoka M, Hayashi A, Fukunaga M, Shirouzu K. Successful treatment of sternal osteomyelitis after pneumonectomy using pedicized omentum flap. *Jpn J Thorac Cardiovasc Surg* 2001; 49: 522-4.
- Nishida H, Grooters RK, Soltanzadeh H, Thieman KC, Schneider RF, Kim WP, et al. Discriminate use of electrocautery on the median sternotomy incision. *J Thorac Cardiovasc Surg* 1991; 101: 488–94.
- Bitkover CJ, Cederlund K, Aberg B, Vaage J. Computed tomography of the sternum and mediastinum after median sternotomy. *Ann Thorac Surg* 1999; 68: 858 - 63.
- Gilmanov D, Bevilacqua S, Murzi M, Cerillo AG, Gasbarri T, Kallushi E, et al. Minimally invasive and conventional replacement of the aortic valve: analysis of the propensity index. *Ann Thorac Surg* 2013; 96: 837-43.
- Cosgrove DM 3rd, Sabik JF. Minimally invasive approach to operations on the aortic valve. *Ann Thorac Surg* 1996; 62: 596–7.
- Svensson LG. Minimal access "J" or "j" sternotomy for valvular, aortic, and coronary operations or reoperations. *Ann Thorac Surg* 1997; 64:1501–3.
- Young CP, Sinha S, Vohra HA. Outcomes of minimally invasive aortic valve replacement surgery. *Eur J Cardiothorac Surg* 2018; 53 Suppl 2: ii19–ii23.
- Semsroth S, Gote RM, Wright IR, de Brabandere K, Hanspeter E, Kilo J. Comparison of two minimally invasive techniques and median sternotomy in aortic valve replacement. *Ann Thorac Surg* 2017; 104: 877-83.
- Yasakova EP, Zyablova EI, Agurina NV, Shevchenko EG, Belash SA, Boldyrev SY. Possibilities of multispiral computed tomography in the diagnosis of combined cardiac pathology before and after surgical correction. *Innovative medicine of Kuban* 2017; 7: 47-50.
- Rykov AE. Differences in topography and anatomical characteristics of the heart according to computed tomography. *Bulletin Orenburg State University* 2011; 135: 335.
- Plass A, Scheffel H, Alkadi H, Kaufman, Genoni M, Falk V, et al. Replacement of the aortic valve using a minimally invasive approach: preoperative planning, surgical technique and result. *Ann Thorac Surg* 2009; 88: 1851–6.
- Boti R, Hindori VG, Schade EL, Kougioumtzoglou AM, Verbeek EC, Driessen-Waajier A, et al. Minimal invasive aortic valve replacement: associations of radiological assessment with procedure complexity. *J Cardiothorac Surg* 2019; 14: 173.
- Glauber M, Gilmanov D, Farneti PA, Kallushi E, Micheli A, Chiamonti F, et al. Right anterior minithoracotomy for aortic valve replacement: 10 years of experience in a single center. *J Thorac Cardiovasc Surg* 2015; 150: 548–56.
- Fabre O, Durand F, Hysi I. A novel computed tomography scout for patient selection in minithoracotomy in aortic replacement. *Ann Thorac Surg* 2020; 110: e339-41.
- Welp HA, Herlemann I, Martens S, Deschka H. Outcomes of aortic valve replacement via partial upper sternotomy versus conventional aortic valve replacement in obese patients. *Interact Cardiovasc Thorac Surg* 2018; 27:481-6.
- Mikhalevich T, Kon LKh, Unik D, Aranki SFF, Cooper GS, Byrne JG. A thousand minimally invasive valve surgeries: early and late results. *Ann Surg* 2004; 240: 529–34.
- Schmitto JD, Mohr FW, Con LH. Minimally invasive aortic valve replacement: how does it work in high-risk patients? *Curr Opin Cardiol* 2011; 26: 118–22.
- Khoshbin E, Prayaga S, Kinsella J, Sutherland FW. Minimal-invasive for aortic valve replacement shortens the length of stay in the cardiac intensive care unit: a meta-analysis of randomized controlled trials. *BMJ* 2011; 1: e000266:1–5.
- Kirmanian BH, Jones SG, Malaisri SK, Chung DA, Williams RJ. Limited and complete sternotomy for aortic valve replacement. *Cochrane Library*; 2017.
- Miceli A, Murzi M, Gilmanov D, Fuga R, Ferrarini M, Solinas M, et al. Minimally invasive replacement of the aortic valve using the right minithoracotomy is associated with better results than ministernotomy. *J Thorac Cardiovasc Surg* 2014; 148: 133 –7.
- Snegirev MA, Payvin AA, Denisjuk DO, Khvan NE, Sichinava LB. Outcomes of the minimally invasive aortic valve replacement. *Grekov's Bulletin of Surgery* 2019; 178: 16-20.
- Dzhundubaev M.K. Minimally invasive technique of aortic valve replacement. Dissertation of candidate of medical science. 2007; Bishkek, Kyrgyzstan



Afternoon around the castle of Vorselaar 2022. Christiaan Vrints, Antwerp, Belgium