

# Remodeling of the microcirculation of the small intestine with a fatty diet in rats: an experimental randomized study

Bolotbek Alymzhan uulu<sup>1a</sup>, Elmira M. Mamytova<sup>1a,2</sup>, Yusuf X-M. Shidakov<sup>3</sup>, Aicholpon T. Israilova<sup>1a</sup>, Aina J. Mamytova<sup>1b</sup>, Rustam R. Tukhvatshin<sup>1c</sup>, Tamara S. Abaeva<sup>4</sup>, Nurbek K. Monolov<sup>2</sup>, Amanbek M. Mamytov<sup>5</sup>

<sup>1a</sup>Department of Neurology and Clinical Genetics named after A.M. Murzaliev, <sup>1b</sup>Department of Pathological Physiology and

<sup>1c</sup>Department of Normal and Topographic Anatomy Kyrgyz State Medical Academy named after I.K. Akhunbayev, Bishkek, Kyrgyz Republic

<sup>2</sup>Laboratory for Modeling of Pathological Processes of the Medical Faculty of the Kyrgyz-Russian Slavic University named after B.N. Yeltsin, Bishkek, Kyrgyz Republic

<sup>3</sup>Department of Internal Medicine of the Kyrgyz State Medical Institute of Retraining and Advanced Training named after S.B. Daniyarov, Bishkek, Kyrgyz Republic

<sup>4</sup>Department of Clinical Disciplines. Salymbekov University, Bishkek, Kyrgyz Republic

<sup>5</sup>Kyrgyz State Medical Academy named after I.K. Akhunbayev, Bishkek, Kyrgyz Republic

## Abstract

**Objective:** To study the remodeling of hemo- and lymphomicrocirculation pathways and structures of the membranes of the small intestine in rats on isolated fatty diet.

**Methods:** The study design is an experimental randomized study. A population of twenty 7-month-old Wistar rats, sexually mature male rats with weight 200-250 gr were divided into main (10 animals) and control (10 animals) groups. The main group was subjected exclusively to a fat diet, and the control group was on standard feed for a month. The age and body weight of the animals were measured and compared in the beginning of the experiment and before autopsy. On the 30th day, the animals were removed from the experiment and a histological analysis with morphometry of inner layer of small intestine and identification of changes in the microcirculatory bed were performed. The t-criterion of independent and paired samples was used for statistical analysis.

**Results:** The animals in both groups were comparable by age and body weight. Over time, the weight of some animals decreased in each group (217.5 (18.5) gr vs. 211.8(18.2) gr, (p=0.0001) for the main group and increased 206.2 (10.6) gr vs. 240.6 (11.7) gr, (p=0.0001) for the control group). Remodeling of the small intestine is observed with noticeable changes in its morphology, manifested in a decrease in the height and thickness of the villi, as well as the thickness of the muscle layer, the depth of crypts and a reduction in the number of goblet cells. The above morphological changes are accompanied with inactivity of the villi capillaries and a sharp decrease in capillary blood flow. The absence of coarse feed in the diet of animals led to hypotrophy of the muscular lining of the small intestine. On the 30th day, in many villi, the bloodstream resembled the appearance of a burnt tree or bush, as individual capillary loops open and their venular ends disappear.

**Conclusion:** Remodeling of the bloodstream vessels was observed in all layers of the small intestine in rats on fatty diet. Insufficiency of the vascularization of the mucous membrane of the small intestine was associated on the one hand with a change in all types of cell populations of the mucous membrane with their reduction, and on the other hand with hypofunction of the blood vessels of the villi of the small intestine and lymphostasis.

**Key words:** diet, high-fat, rats Wistar, intestine small, microcirculation, remodeling

(Heart Vessels Transplant 2024; 8: 178-90. doi: 10.24969/hvt.2024.483)

**Address for Correspondence:** Elmira M. Mamytova, Department of Neurology and Clinical Genetics named after A.M. Murzaliev, Kyrgyz State Medical Academy named after I.K. Akhunbaev, Bishkek, Kyrgyzstan

**Mobile:** +996551325314 **Email:** elmiramamytova@yahoo.com

**ORCID:** Bolotbek Alymjan - 0000-0001-9082-7279; Elmira M. Mamytova - 0000-0002-4322-5555; Yusuf Kh-M Shidakov - 0000-0002-2779-5574; Aicholpon T. Israilova-0009-0007-4268-7591; Aina Dj. Mamytova - 0009-0007-1637-6984; Rustam R. Tuhvatshin- 0000-0002-9329-8568; Tamara S. Abaeva- 0000-0002-1996-4737; Nurbek K. Monolov- 0000-0001-7589-5820; Amanbek M. Mamytov-0009-0008-1881-4877

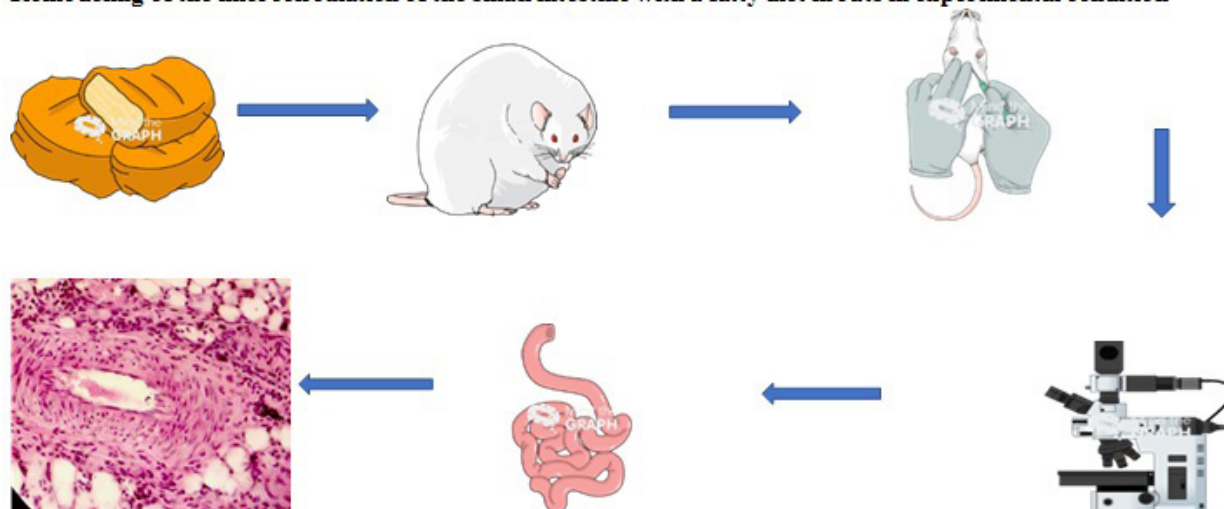
**Citation:** Alymzhan uulu B, Mamytova EM, Shidakov YX-M, Israilova AT, Mamytova AJ, Tukhvatshin RR, et al. Remodeling of the microcirculation of the small intestine with a fatty diet in rats: an experimental randomized study. Heart Vessels Transplant 2024; 8: 178-90. doi: 10.24969/hvt.2024.483

**Received:** 17.01.2024 **Revised:** 13.03.2024 **Accepted:** 15.04.2024

**Copyright ©2024 Heart, Vessels and Transplantation**

## Graphical abstract

### Remodeling of the microcirculation of the small intestine with a fatty diet in rats in experimental condition



## Introduction

The small intestine is one of the most important departments of the digestive tract, where the final digestion and absorption into the blood of the products of conversion (metabolism) of proteins, carbohydrates and fats take place. In the structural organization, the microcirculatory bed of the small intestine is constructed in such a way that its functional specialization is most optimally performed. If the villi of the small intestine are considered a structural functional unit of the mucous membrane, then the microcirculatory bed acts as an integral part of this unit (1). The fact is that the angion of the villi and the microcirculatory bed of the small intestine not only provide oxygen and nutrient to all layers of the organ, but also act as necessary elements for the absorption and transportation of digested products from the small intestine to the liver, with the exception of fat metabolites (2).

Processed by enzymes, emulsified with bile acids, fat droplets in the form of chylomicrons are absorbed into the lymphatic capillaries of the villi (3). The question arises of course about the nature of remodeling of the hemomicrocirculation of the small intestine when there are no proteins and carbohydrates in the diet. Their decomposed products are absorbed into the blood. No less interesting is the question of changes in lymphatic capillaries, when the functional load increases sharply with an exclusively fatty diet. In other words, what causes hypofunction of the blood vessels and hyperfunction of the lymphatic vessels of the small intestine with a monotonous fat diet is not well known.

This problem is of theoretical interest in the aspect of clarifying the conjugacy of changes in structural organization from the state of functional specialization of the small intestine within its wall. At the same time, the practical, clinical significance of

the problem is revealed, since the morbidity of the digestive tract diseases, including the small intestine, largely depends on the state of the diet.

Meanwhile, our literature search concerning the discussed problem here was not successful; we did not find information about the effect of an exclusively fatty diet on the structural organization and functional specialization of the microcirculatory bed of the small intestine with a fatty diet.

Research objective of the study was to investigate microcirculation of the small intestine of animals subjected to an isolated fat diet and describe in the form of histomorphological changes.

## Methods

Study design: experimental randomized study.

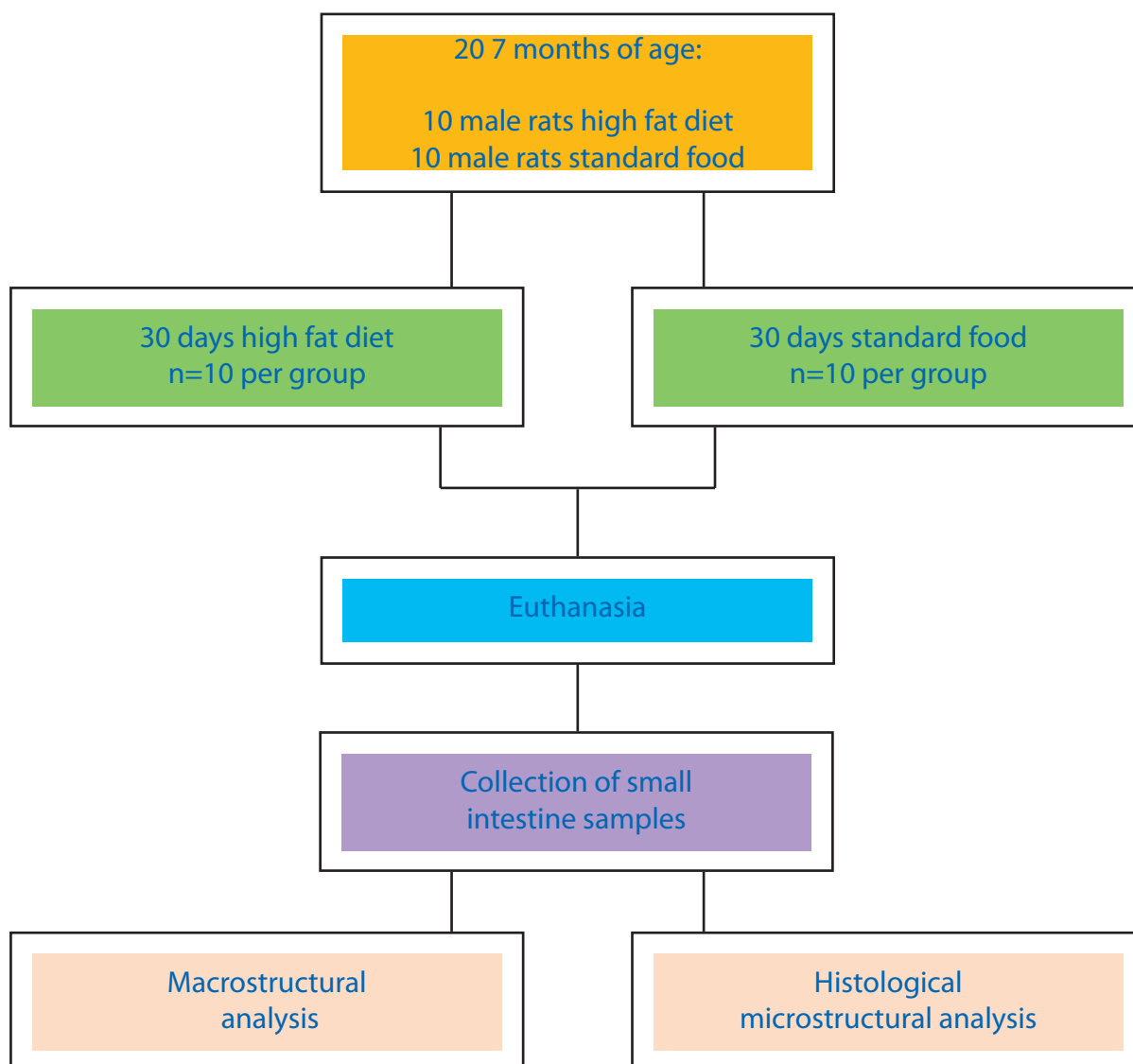
Study population and intervention: Twenty 7-month-old healthy and sexually mature male Wistar rats with weight 200-250 gr were included in our study. Rats younger than 7 months and females were excluded. Twenty male rats were randomly divided by number into two groups (n=10 rats per group): control (standard food) and experimental (high fat diet).

The place of the study and ethical issues: The study was conducted on the basis of the laboratory of experimental modeling of pathological processes of the Kyrgyz-Russian Slavic University (KRSU) in compliance with the rules of the methodological recommendations of the GRP and laboratory practice approved by Order No. 708 of the Ministry of Health and Social Development of the Russian Federation dated August 23, 2010 "On approval of the rules

of laboratory practice". The staff of the vivarium cared for and fed the rats in accordance with international standards for experimental work on animals (Consensus Guidelines on Animal Ethics and Welfare 2010). The maximum density in the cage was three animals of the same group. All efforts have allowed us to standardize all procedures to minimize

the number of animals used and their suffering. The protocol of the study was approved by the local ethics committee of the non-government organization "Preventive Medicine" of the Ministry of Health of the Kyrgyz Republic.

The order of experimental procedures was carried out according to the ARRIVE protocol and is shown in Figure 1.



**Figure 1. The order of experimental procedures according to the ARRIVE protocol**

### Diet

The initial age and body weight were compared with these parameters measured before slaughter. The animals were randomly divided into the main and control groups based on an isolated fat "diet" and standard feeding. The isolated fat diet consisted of fat-tailed, while the standard feeding contained second-grade wheat flour, oatmeal, cow's milk, table salt, herbs, meat - young pork. The high-fat diet

consisted exclusively of fat, where the proportion of fat was 100% and the proportion of fat in the standard diet was 30% (Table 1).

The animals were fed with appropriate "diets" and free access to water for up to 30 days. On the 30th day, laboratory rats were randomly selected and slaughtered for histomorphological analysis of the small intestine. The animals were equally planned for each excision time.

<b>Table 1. The composition of a high-fat and standard diet</b>		
<b>Nutrients</b>	<b>High fat diet</b>	<b>Normal rat standard diet</b>
	<b>% /100 gr</b>	<b>%/100gr</b>
<b>Carbohydrate</b>	0	49
<b>Protein</b>	0	21
<b>Fat</b>	100	30
<b>Total energy, kcal/100gr</b>	902	396

The age and body weight of the animals were measured and compared at the beginning of the experiment and before autopsy.

### Histological preparation of tissue samples

A totally 20 animals (10 in each group) were used for histological analysis. Histological analysis was performed on the 30th day to establish the onset of pathological changes, which can be taken as a point of view when studying the nature of restorative reactions later. After the finishing of experiment, the animals were subjected to general anesthesia. Next, in some animals, the mixture of black carcass on 10% neutral formalin in a ratio of 1:4 was injected in the bloodstream through the abdominal aorta. Fragments of the small intestine were fixed in a 10% neutral formalin solution, dehydrated in alcohols of increasing concentration, followed by the manufacture of paraffin blocks. Histological sections 5-7 microns thick were stained with hematoxylin-eosin and both gross and microscopic changes were studied. An Olympus BX40 light microscope equipped with a Levenhuk C130 NG digital camera and a PC was used for microscopic analysis.

### Histomorphological analysis

Each section of the small intestine was stained with hematoxylin and eosin (HE) for descriptive and morphometric analysis and for identification and quantification of mucosal cells (cell populations). Using images taken by a camera in combination with a trinocular microscope, the depth of the crypts, the height and thickness of the villi, and thickness of the muscle layer were measured. For measurements, four fields were photographed for each of the 10 animals from 2 groups. Each histological section was divided into squares, and images were taken from four different areas of the small intestine. The depth of the crypts, the height and thickness of the villi, as well as the thickness of the muscle layer were calculated based on 20 random measurements in an animal in

each segment stained with HE. A quantitative assessment of the number of goblet cells was performed. All measurements were performed using Axio Vision Rel. 4.5 Software (Zeiss). A further comparison of the histomorphological data of the control and main groups of animals was carried out.

### Statistical analysis

The statistical analysis was carried out using STATA 2023 software. Continuous variables are denoted by the mean and standard error of mean. An independent two-sample t-test was used for comparing age and body weight between the main and control groups. The initial and pre-slaughter values were analyzed separately. In addition, a t-test of paired samples was performed to see potential changes within each group. A p value of less than 0.05 is considered statistically significant.

### Results

#### Initial demographic data and comparison results

Ten laboratory rats were subjected to an isolated fat diet with their peers, who were fed a standard diet, so twenty animals were evenly distributed among the experimental and control groups. No premature deaths or other events were observed during the experimental period. The initial average age of the main group was 7.6 (0.18) months, in the control group – 7.5 (0.18) months with insignificant differences ( $p=0.49$ ). The initial average body weight was 217.5 (6.5) gr versus 211.8 (3.7) gr ( $p=0.46$ ) in the main and control groups, respectively. Results of the t-test of independent samples demonstrated statistically significant difference between groups in relation to the weight of animals, which was lower after 30 days in animals of main group as compared to control ( $p<0.05$ ). Analysis of changes after 30 days of diets within groups demonstrated increase of weight in control and decrease of weight in main group ( $p=0.0001$  for both). Animals of both groups aged during observation ( $p=0.0001$  for both) (Table 2).

<b>Table 2. Age and weight of animals before and after autopsy in main and control groups</b>			
<i>Results of the t-test of independent samples</i>			
<b>Variables</b>	<b>MG (n=10)</b>	<b>CG (n=10)</b>	<b>p (MG vs CG)</b>
<b>Age BL, months.</b>	7.6 (0.53)	7.5 (0.53)	0.49
<b>Weight BL, g</b>	217.5 (18.5)	211.8 (10.6)	0.46
<b>Age of PA, months</b>	8.6 (0.72)	8.5 (0.53)	0.56
<b>Weight PA, g</b>	206.2 (16.2)	240.6 (11.7)	0.05
<i>Results of paired t - test</i>			
<b>Variables</b>	<b>MG (n=10)</b>	<b>CG (n=10)</b>	<b>P (BL vs PA)</b>
<b>Age BL, months</b>	7.6 (0.53)	7.5 (0.53)	0.0001
<b>Weight BL, g</b>	217.5 (18.5)	211.8 (10.6)	0.0001
<b>Age PA, months</b>	8.6 (0.72)	8.5 (0.53)	0.0001
<b>Weight PA, g</b>	206.2 (16.2)	240.6 (11.7)	0.0001

Data are expressed as the mean (SEM)  
 BL – baseline, CG – control group, g – grams, MG – main group, PA – preliminary autopsy.

At the end of the experiment, the animals had tousled hair with a slightly yellowish light. Baldness was noted on the abdomen and tail. Contrary to expectations, the weight of the animals did not increase as a result of obesity compared to the control data. On the contrary, weight loss was observed in individual animals; upon autopsy, a decrease in subcutaneous fat was noted, the fatty suspension of the colon and the fatty layer of the mesentery of the small intestine looked empty, swollen and transparent.

When injected with ink through the abdominal aorta, the small intestine acquired a mottled appearance due to uneven filling with the injected mass. While this was not observed in animals kept on standard feed. Before presenting the data obtained from animals kept on an exclusively fatty diet, we considered it advisable to present information about the results of a study of the microcirculatory bed in animals taken for comparison.

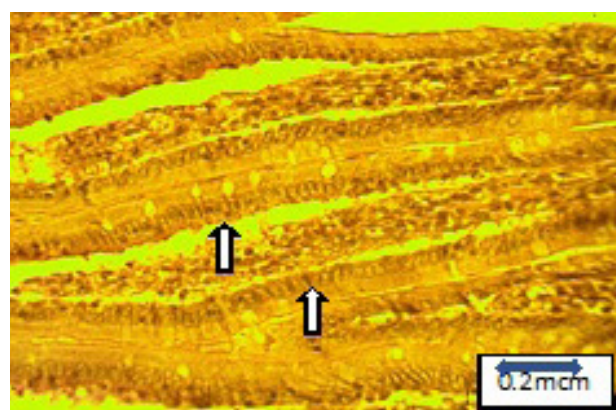
**Morphological analysis**

The vascular bed of the small intestine is normal.

The small intestine is endowed with complex angioarchitectonics capable of ensuring the integrity of the structural organization and the full implementation of the functional specialization of the organ.

The peculiarity of the structural organization of the intestine is that it "can be considered to consist of two tubes inserted into each other. One tube (outer) consists of serous and muscular membranes, and the other (inner) consists of mucosa, with its lamina muscularis mucosae".

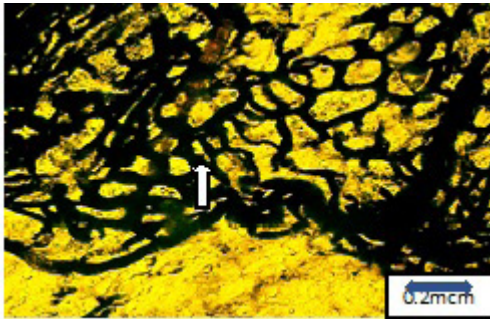
The inner tube performs suction and secretory functions, and the outer one performs a motor function. The specific function of each tube is provided by the appropriate structural substrate, blood and lymph circulation and innervation. Thus, the mucous membrane of the small intestine is endowed with villi, which are outgrowths of its own plate of the mucous membrane. They are covered with a single-layer prismatic epithelium, which includes goblet-shaped, cone-shaped cells and cells of the diffuse neuroendocrine system (DNES) (Fig.2).



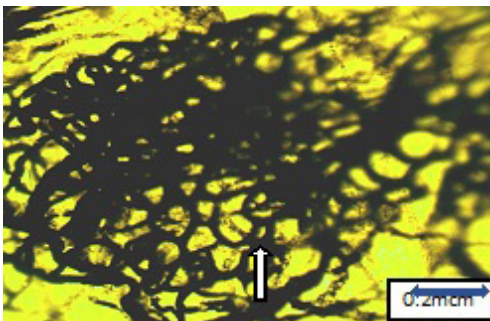
**Figure 2. Control group. The villi of the small intestine are covered with a prismatic epithelium, which includes goblet-shaped and tubular cells. Filling in paraffin. H&E staining. X400**

The mucous membrane of the small intestine is supplied with blood by the submucosal vascular plexus. Arteries branch off from the submucosal vascular plexus - villous

arterioles, which in the villi break up into capillaries forming an entire venous network of channels (Fig.3, 4).



**Figure 3. Control group. Arterioles, capillary and venous network of two papillae of the mucous membrane, anastomosing with each other. It is not possible to distinguish the arteriolar and venular sections of the capillaries. An enlightened slice, ink staining X400**



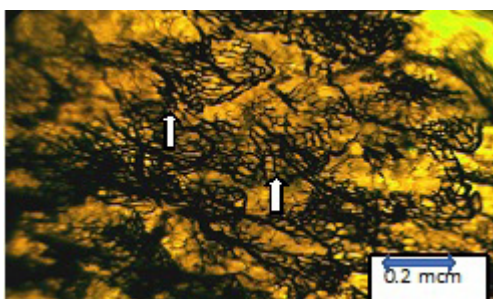
**Figure 4. Control group. The microcirculatory bed. Individual villi of the mucous membrane of the small intestine. An enlightened slice, ink staining X400**

In this network, it is almost impossible to distinguish arterioles from venules, arteriolar and venular sections of capillaries on enlightened preparations. The issue of arteriovenous shunting within the vascular bed of the villi stands out. Since the veins of the small intestine are devoid of valves, the injection mass fills the microcirculatory bed of the villi when injected through both the abdominal aorta and the portal vein. Does this mean that during life, blood flow occurs in both directions, which requires special study?

On histological preparations, finger-shaped, cone-shaped, oval, tongue-shaped villi can be distinguished by shape with

a peculiar angioarchitectonics on enlightened preparations (ladder, fountain, beam, etc.). Ladder and fountain types are more common in cone-shaped and finger-shaped villi.

In the field of view of the microscope at a magnification of 400, there are from 8 to 12 villi with an injected microcirculatory bed. Their concentration is higher where the ladder types are located and less where the bundle types of angioarchitectonics of the villi are



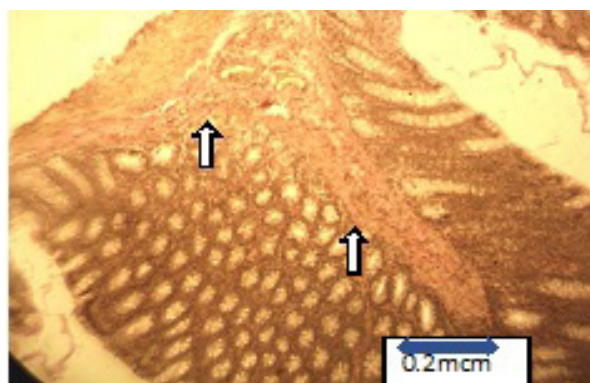
**Figure 5. Control group. Microcirculatory bed of 15 villi of the mucous membrane of the small intestine. An enlightened slice, ink staining X400**

If we consider the villi as a structurally functional unit (element) of the mucous membrane, then its microcirculatory bed performs a double function. The first function, as in other organs, is trophic – it is the supply of oxygen, macro- and micronutrients to the cell population of the epithelium and the removal of metabolic products. The second function - the microcirculatory bed acts as an inseparable part of the structural and functional unit of the mucous membrane - the villi of the small intestine. It is here that macro- and micronutrients absorbed by epithelial cells from the intestinal cavity enter the bloodstream.

The issue of regulating the function of villi and their microcirculatory bed has not been definitively resolved. Based on the literature and our own preliminary data, the following assumption can be made. It is known that

the rim of the mucous membrane of the small intestine is lined with a layer of glycocalyx, which contains not only enzymes, but also an abundance of receptors. It should be assumed that these receptors are able to respond to the structural information of medicines and food and transmit it to the cellular population of the epithelium and the microcirculatory bed. With some caution, it seems possible to think that the work of these receptors is determined to a certain extent by the bioavailability of drugs and nutrients.


Central lymphatic vessels (sinuses) the villi "pour out" into the submucosal lymph plexus. They, like the microcirculatory bed of the villi, perform a double function: 1) drainage - outflow of tissue fluid, 2) absorption – absorption of chylomicrons (Fig.6).



**Figure 6. Control group. Central lymphatic vessels (sinuses) villi. Filling in paraffin. H&E staining. X400**

The muscular vascular and nervous plexus are located in the outer tube, consisting of serous and muscular membranes. The branches of the muscular vascular plexus anastomose abundantly with the branches of the submucosal vascular

plexus. The muscular vascular plexus is abundantly supplied with blood by the circular and longitudinal muscle fibers of the muscular membrane of the small intestine (Fig.7).



**Figure 7. Control group. Branches of the muscular vascular plexus anastomose with branches of the submucosal vascular plexus. An enlightened slice, ink staining. X400**

### Morphometry analysis

In rats of the main group after 30 days period of isolated fat diet, remodeling of the small intestine is observed with noticeable changes in its morphology, manifested in a

decrease in the height and thickness of the villi, as well as the thickness of the muscle layer, the depth of crypts and a reduction in the number of goblet cells.

Morphometric analysis of the intestine showed that in the rats of the main group there was a decrease in the depth of crypts in the duodenum (9%,  $p < 0.05$ ). In addition, the villi height in the animals of the main group was 35% lower than

in the animals of the control group ( $p < 0.0001$ ). The thickness of the villi was also reduced by 34% in the animals of the main group ( $p < 0.05$ ). A complete summary of morphometric analyses is presented in Table 3.

Groups /Variables	Villi height, $\mu\text{m}$	Villi thickness, $\mu\text{m}$	Crypt depth, $\mu\text{m}$	Muscle thickness, $\mu\text{m}$	Goblet cells, %
<b>Main group</b>	308.0 (10.1)	343.0 (9.5)	228.0 (3.1)	109.0 (2.8)	11.0 (0.4)
<b>Control group</b>	475.0 (9.7)	531.0 (13.4)	251.0 (6.0)	126.0 (0.4)	16.0 (1.0)
<b>p</b>	< 0.0001	< 0.0001	< 0.05	< 0.05	< 0.05


Data are expressed as the mean (SEM) and comparisons were made using Student's t-test for independent samples

Vascular bed of the small intestine of rats kept exclusively on a fat diet.

The absence of coarse feed in the diet of animals led to hypertrophy of the muscular lining of the small intestine.

This was combined with the remodeling of angioarchitectonics, which consisted in the rupture of capillary loops, the formation of various blisters and interceptions at the outlet of the injection mass into the

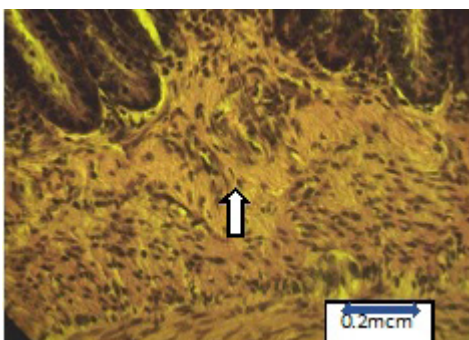
surrounding tissue. Against this background, fragments of arterioles and venules were revealed, which differed little from each other. As a result of intestinal atony and stretching of its wall, the area bounded by square-shaped capillary loops increased, hence it can be concluded that the diffusion distance of the capillaries increased, which reduced the degree of oxygenation of the muscular membrane (Fig. 8).



**Figure 8. High fat diet. Rupture of the capillary bed of the vascular plexus of the muscular membrane, imbibition of the injection mass of the paravasal environment. An enlightened slice, ink staining .X400**

On histological sections, there is a loosening of muscle bundles with elements of fatty degeneration. Individual

muscle fibers undergo myomalacia and partial necrosis (Fig. 9).

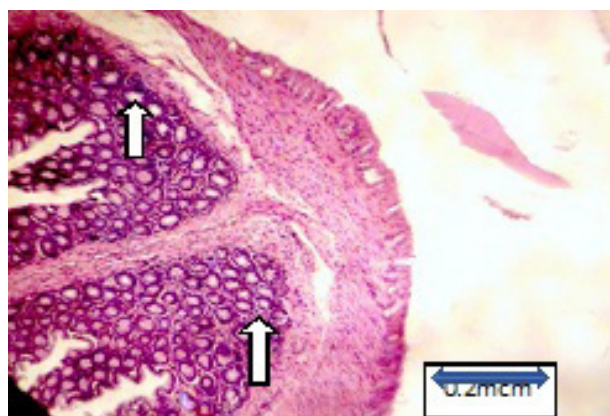


**Figure 9. High fat diet. Swelling of the muscular lining of the small intestine. Filling in paraffin. H&E staining. X400**



In the submucosal layer, the vascular network is discharged and loses its usual architectonics. Areas of hypervascularization are combined with areas of hypo- and vascularization, as a result of which the architectonics typical of the norm is violated. On histological preparations, there is a manifestation of cytotoxic, ionic and vasogenic edema, sometimes microbleeds.

The above changes apparently reduce the extensibility of connective tissue structures; their integrity is violated, which leads to the separation of the serous and muscular membranes from the mucous membrane of its own plate (Fig.10).



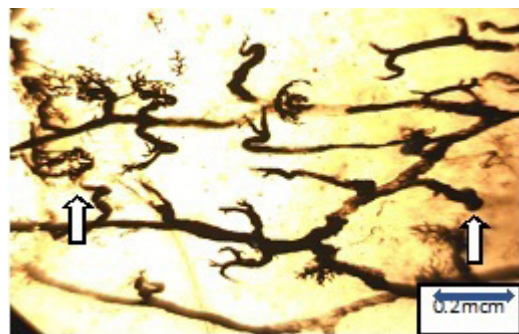**Figure 10. High fat diet. Separation of the muscular membrane from the submucosal plate of the small intestine with the presence of edematous fluid. Filling in paraffin. H&E staining. X400**

Supravitaly peristaltic of the muscular membrane during opening of the abdominal cavity is performed without the corresponding dynamics of the mucous membrane, which leads to stagnation of scarce food in the intestinal cavity, fermentation and bloating.

The own plate of the mucous membrane acquires different thicknesses in different parts of the intestinal tube. Its

In the submucosal layer, the vascular network is discharged and loses its usual architectonics. Areas of hypervascularization are combined with areas of hypo- and vascularization, as a result of which the architectonics typical of the norm is violated. On histological preparations, there is a manifestation of cytotoxic, ionic and vasogenic edema, sometimes microbleeds.

The above changes apparently reduce the extensibility of connective tissue structures; their integrity is violated, which leads to the separation of the serous and muscular membranes from the mucous membrane of its own plate (Fig.10).




**Figure 11. High fat diet. Hypovascularization of the muscular membrane and reduction of branches extending to the outgrowths of the own plate of the mucous membrane of the small intestine. An enlightened slice, ink staining X400**

As a result, the microcirculatory bed of the mucous membrane of the small intestine is discharged. The arterioles entering the base of the villi no longer divide with such

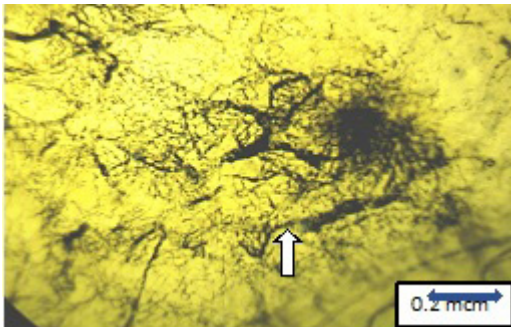
intensity as is normally observed. Many arterioles are not filled with contrast media and the angioarchitectonics of the villi are not detected on the illuminated preparations.

As a result, the number of villi with injected blood vessels per unit area decreases by one and a half, two times (Fig.12).

When examining the capillary bed of a single villi, weak injection, loop breaks, and imbibition of the injection mass into the paravasal environment are noted (Fig.13).



**Figure 12. High fat diet. Angioarchitectonics of the villi of the small intestine is impaired, hypervascularization of the mucous membrane of the small intestine is noted. An enlightened slice, ink staining. X400**

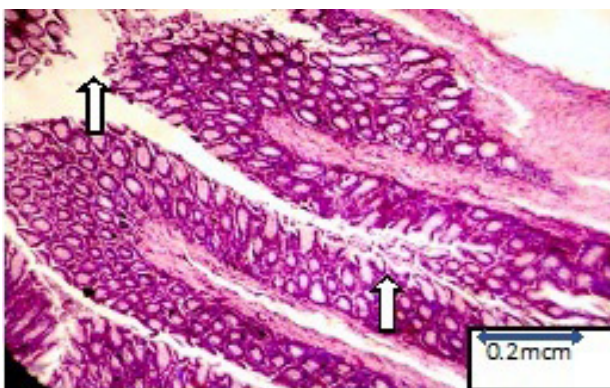


**Figure 13. High fat diet. Angioarchitectonics of a single villi of the mucous membrane with impaired capillary bed. An enlightened slice, ink staining X400**

In many villi, the bloodstream resembles the appearance of a burnt tree or bush, as individual capillary loops open and their venular ends disappear. It should be assumed that a violation of the vascularization of the mucous membrane of the small intestine with an exclusively fatty diet is associated, on the one hand, with a violation of the structure of the vascular wall and hemorheology in the arterial bed of the mesentery, and on the other – with hypofunction of the blood vessels of the villi of the small intestine.

The capillary bed of the villi, aimed at the absorption of metabolites of proteins and carbohydrates in their absence in food, does not experience an appropriate load. Therefore, they undergo partial obliteration.

Against this background, changes in all types of cell populations of the mucous membrane are observed on histological preparations, prismatic cells lose their edge and the glycocalyx covering it (Fig.14).

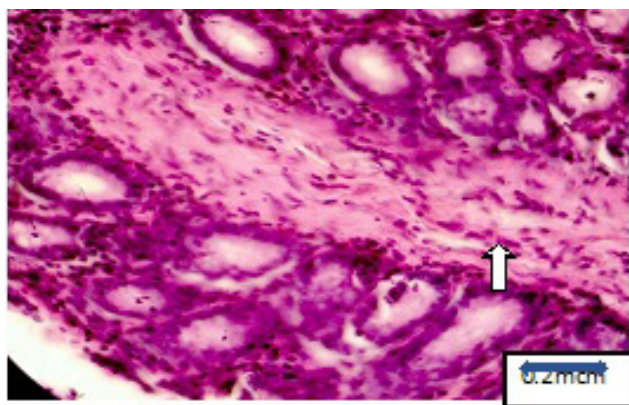


**Figure 14. High fat diet. Villi without edges and glycocalyx. Filling in paraffin. H&E staining. X400**

And this cannot disrupt the sensitivity of the receptors to the contents of the intestine. Prismatic cells look shortened, edematous. Goblet cells are reduced.

On the contrary, the lymphatic capillaries are dilated, filled with lymphocytes and chylomicrons. In general,

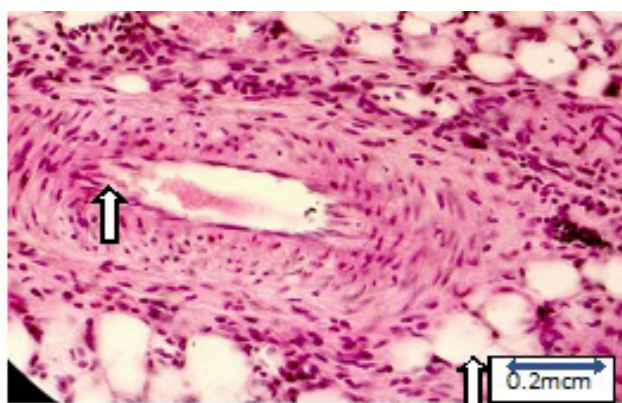
lymphostasis and plasmorrhagia of the processes, the own plate of the mucosa covered with epithelium, are observed (Fig.15).



**Figure 15. High fat diet. Lymphostasis and plasmorrhagia of the processes of the own plate of the mucous membrane of the small intestine. Filling in paraffin. H&E staining. X400**

In all layers of the small intestine, remodeling of the bloodstream of blood vessels is observed not only on enlightened, but also on histological sections. The arteries localized along the intestine are spasmodic, the walls are

thickened, the adventitia is edematous, and the nuclei of the muscular membrane are located randomly. Edematous endothelial cells in certain areas are "palisaded" into the lumen of the vessel (Fig.16).



**Figure 16. High fat diet Edematous endothelial cells are "often" protruded into the lumen of the vessel, there is an overgrowth of longitudinal muscle fibers under the epithelium, edema adventitia is noted. Filling in paraffin. H&E staining. X400**

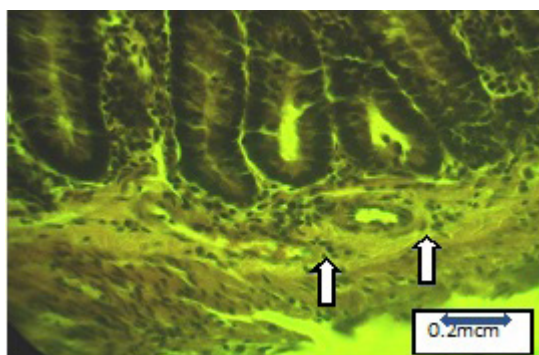
In the submucosal layer, the arteries and veins are atonic, ellipsoid-shaped arteries with edematous adventitia with slits and lacunae of the muscular membrane with swollen endothelial cells surrounded by paravasal edema (Fig.17).

Veins collapsed with uneven sections of wall thickness. Endotheliocytes, approaching each other, block the lumen of the vessels. Arterioles with hypertrophied precapillary sphincters are characterized by plasmorrhage of the vascular wall (Fig. 18).

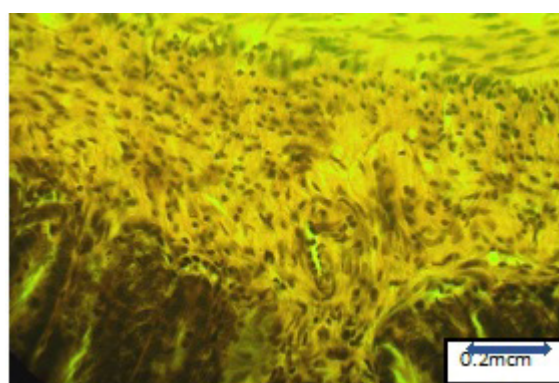
## Discussion

As the literature data show, there is a large gap in relation to information about the effect of nutrition consisting exclusively of fat on the hemo- and lymphocirculatory system of the small intestine on a healthy and diseased organism.

As shown by weighing animals of both groups before and after the experiment, the animals that were on an isolated fat diet for 30 days lost weight in the main group because there were not enough other macro- and micronutrients.



**Figure 17. High fat diet. Atony of arteries and veins in the submucosal layer of the small intestine. Filling in paraffin. H&E staining. X400**



**Figure 18. High fat diet Plasmorrhagia of the vascular wall. Filling in paraffin. H&E staining. X400**

This was also facilitated by those structural disorders in the mucous membrane of the small intestine, which we verified by histological methods and presented in the section results of the study. The latter limited the intestinal absorption function and led to steatorrhea. Other researchers also point to this fact (4-6).

In rats of the main group after 30 days period of isolated fat diet, remodeling of the small intestine is observed with noticeable changes in its morphology, manifested in a decrease in the height and thickness of the villi, as well as the thickness of the muscle layer, the depth of crypts and a reduction in the number of goblet cells.

We have established that an isolated fatty diet (fat tail of sheep) leads to atony of the muscular membrane of the small intestine and dystrophy. A decrease in peristalsis is accompanied by hypovascularization of the serous and muscular membranes. This is also facilitated by the remodeling of the branches of the mesenteric arteries supplying blood to the small intestine. Since an exclusively fatty diet causes exceptional fatty liver disease, the outflow of venous blood from the small intestine into the portal channel is disrupted. The blood supply to the small intestine becomes dependent on portal blood flow and a decrease in such and systemic hemodynamics.

Due to the absence of valves in the sources of the normal flow, a pendulum-like flow of venous blood from the small intestine to the liver and back occurs (7). Venous congestion and swelling of the submucosal layer of the small intestine develop. Edematous fluid stratifies the wall of the small intestine into two tubes, one of which consists of serous and muscular membranes, the other of its own plate and the mucous membrane itself.

Against this background, blood flow through the arterioles extending from the vascular plexus of the muscular membrane and partially from the submucosal layer and protruding processes of its own plate into the villi of the mucous membrane is disrupted. The angioarchitectonics of the villi changes dramatically.

First of all, the capillarization of arterioles ends before reaching the tip of the villi. The architectonics of the villi decreases in volume. The number of villi with injected capillaries in the field of view of the microscope, as well as the number of capillaries of individual villi, becomes scarce.

Remodeling of the angioarchitectonics of the villi of the mucous membrane of the small intestine with an exclusively fatty diet may be due to the lack of proteins and carbohydrates in animal feed. After all, metabolites of proteins and carbohydrates, which must be absorbed into

the bloodstream of the villi, are absent with an exceptionally fatty diet. This reduces the functional significance of angioarchitectonics, which in itself could lead to capillary reduction. The lack of a substrate for absorption led to inactivity of the villi capillaries and a sharp decrease in capillary blood flow. Of course, changes in the blood supply to the digestive tract as a result of a violation of hemorheology with a monotonous fat diet cannot be discounted (8).

The lymphatic vessels located in the center of the villi, unlike blood capillaries, experience a high functional load due to the intake of large amounts of triglycerides. The lymphatic vessels filled with chyme and lymphorrhagia give the processes of their own plate of the mucous membrane in the center of the villi the appearance of jelly. When taking (sampling) blood for biochemical studies, plasma opalesces due to the increased content of chylomicron in it. The biosynthesis of cholesterol from fatty acids, the formation of ketone bodies, lipoproteins and other fat metabolites is disrupted, which leads to vascular, intravascular and extravascular changes in the small intestine.

### Study limitations

Experiments have been conducted to study the short-term effects of an isolated fat diet. To obtain a more complete picture of the effect of an isolated fat diet on the small intestine of the studied object, it is necessary to conduct a study of the effect of a long-term high-fat diet.

### Conclusion

In all layers of the small intestine, remodeling of the bloodstream of blood vessels is observed not only on enlightened, but also on histological sections. The arteries localized along the intestine are spasmodic, the walls are thickened, the adventitia is edematous, the nuclei of the muscular membrane are located randomly.

Violation of the vascularization of the mucous membrane of the small intestine with an exclusively fatty diet is associated, on the one hand, with a violation of the structure of the vascular wall and hemorheology in the arterial bed of the mesentery, and on the other – with hypofunction of the blood vessels of the villi of the small intestine. Lymphostasis and plasmorrhagia of villi are observed in the lymphatic capillaries.

Against this background, changes in all types of cell populations of the mucous membrane are observed on histological preparations. Prismatic cells shorten, become edematous. Goblet cells are reduced.

**Ethics:** The staff of the vivarium cared for and fed the rats in accordance with international standards for experimental work on animals (Consensus Guidelines on Animal Ethics and Welfare 2010). The protocol of the study was approved by the local ethics committee of the non-government organization "Preventive Medicine" of the Ministry of Health of the Kyrgyz Republic

**Peer-review:** External and internal

**Conflict of interest:** None to declare

**Authorship:** B. A-U., E.M. M., Y.X-M.S., A.T.I., A.J.M., R.R.T., T.S.A., N.K.M., and A.M.M. equally contributed to preparation of manuscript and fulfilled authorship criteria

**Acknowledgement and funding:** None to declare

**Statement on A.I. - assisted technologies:** None to declare

### References

1. Kiela PR, Ghishan FK. Physiology of intestinal absorption and secretion. *Best Pract Res Clin Gastroenterol* 2016; 30: 145-59. doi: 10.1016/j.bpg.2016.02.007
2. Knoblauch M, Holliger C. Mikrozirkulationsstudien am Villus des Rattendünndarmes in vivo (Microcirculation studies on rat small intestine villi in vivo). *Schweiz Med Wochenschr* 1977; 107: 1391-9.
4. Lee JC, Lee HY, Kim TK, Kim MS, Park YM, Kim J, et al. Obesogenic diet-induced gut barrier dysfunction and pathobiont expansion aggravate experimental colitis. *PLoS One* 2017; 12: e0187515. doi:10.1371/journal.pone.0187515
5. Tanaka S, Nemoto Y, Takei Y, Morikawa R, Oshima S, Nagaishi T, et al. High-fat diet-derived free fatty acids impair the intestinal immune system and increase sensitivity to intestinal epithelial damage. *Biochem Biophys Res Commun* 2020; 522: 971-7. doi:10.1016/j.bbrc.2019.11.158
6. Do TT, Hindlet P, Waligora-Dupriet AJ, Kapel N, Neveux N, Mignon V, et al.. Disturbed intestinal nitrogen homeostasis in a mouse model of high-fat diet-induced obesity and glucose intolerance. *Am J Physiol Endocrinol Metab* 2014; 306: E668-80. doi:10.1152/ajpendo.00437.2013
7. Covasa M, Ritter RC. Adaptation to high-fat diet reduces inhibition of gastric emptying by CCK and intestinal oleate. *Am J Physiol Regul Integr Comp Physiol* 2000; 278: R166-70. doi: 10.1152/ajpregu.2000.278.1.R.166
8. Tanaka S, Nemoto Y, Takei Y, Morikawa R, Oshima S, Nagaishi T, et al. High-fat diet-derived free fatty acids impair the intestinal immune system and increase sensitivity to intestinal epithelial damage. *Biochem Biophys Res Commun* 2020; 522: 971-7. doi: 10.1016/j.bbrc.2019.11.158