

Presentation

A routine follow-up twelve-lead ECG (Fig. 1) is performed in a 70 years old male patient implanted with a dual-chamber

pacemaker for sick sinus syndrome two years ago (Model Reply DR, Sorin). The patient is strictly asymptomatic.

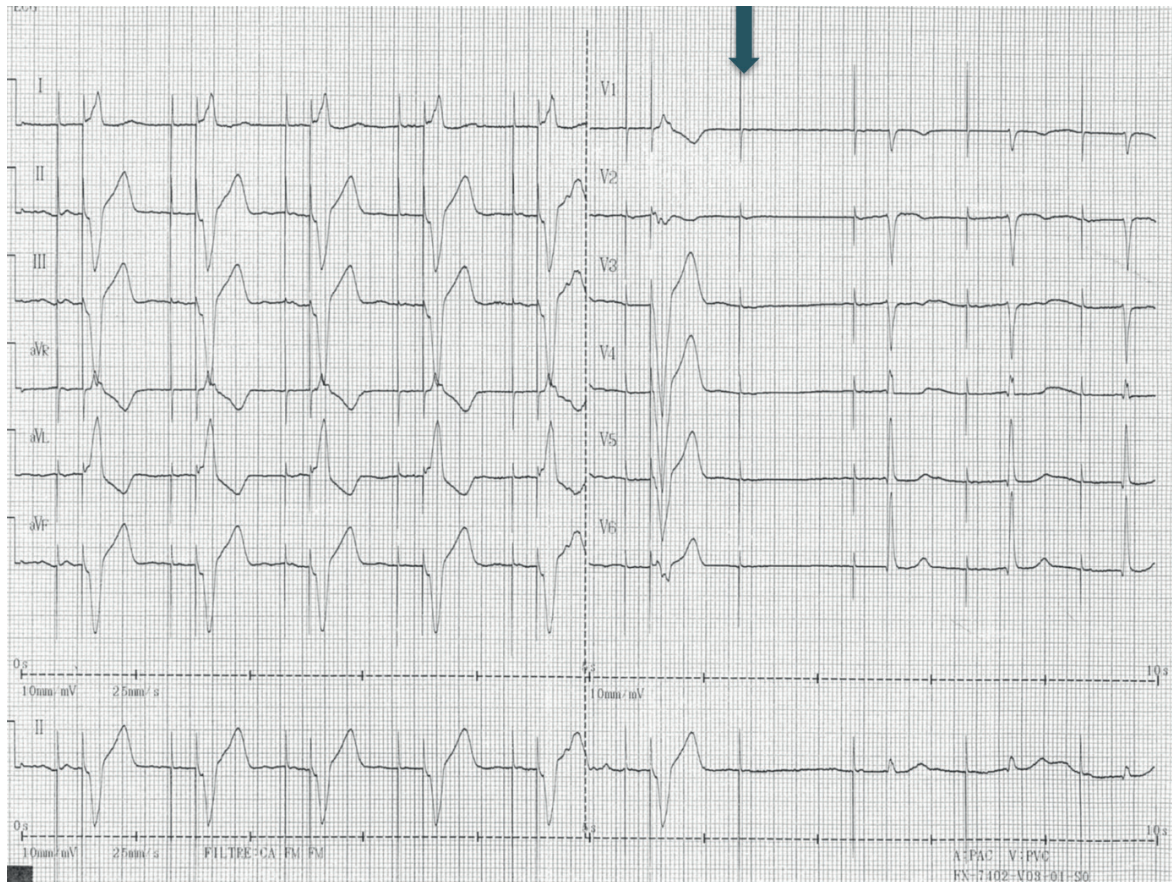


Figure 1. Electrocardiogram tracing

Sok-Sithikun Bun, Karim Hasni

Cardiology Department,

Princess Grace Hospital, Monaco

Peer-review: internal

Conflict of interest: None to declare

Authorship: S.S.B. and K.H. equally contributed to preparation of quiz

Acknowledgement and funding: None to declare

What is the most likely explanation for the 7th beat ?

- 1/ There is an intermittent ventricular pacing dysfunction.
- 2/ There is an intermittent atrial pacing dysfunction.
- 3/ There is no dysfunction.
- 4/ There may be some noise on the ventricular lead.

Address for Correspondence: Sok-Sithikun Bun, Cardiology Department, Princess Grace Hospital, Monaco
Email: sithi.bun@gmail.com Phone : +377 97 98 97 71 – Fax : + 377 97 98 97 32

Received: 23.03.2019 **Accepted:** 24.03.2019

Copyright© 2019 Heart, Vessels and Transplantation