

CT and MR images of cystic adventitial disease of the popliteal artery

Kairgeldy Aikimbaev

Department of Radiology, Medical Faculty, Cukurova University, Adana, Turkey

Cystic adventitial disease (CAD) is a very rare vascular disorder with prevalence as low as 1:1000 of all vascular pathologies (1). This disease most frequently occurs in young or middle-aged male patients with male/female ratio of 5/1 (1). CAD causes cystic degeneration of peripheral arteries; however, rarely, veins can also be involved (2). Although the most frequently detected location of CAD is the popliteal artery (usually unilateral), any peripheral artery adjacent to the joint can be affected (3). As a result, luminal narrowing or even occlusion may develop due to external compression presenting clinically as intermittent claudication. Pathologic findings of CAD include intramural cysts containing gelatinous material located between the media and the adventitia. Histopathologic examinations report contents of fibrinogen, hyaluronic acid, hydroxyproline, or mucin within the cyst (3).

The etiology of CAD is unclear. Several hypotheses including developmental, ganglionic, microtraumatic and degenerative causes have been proposed (4). The developmental hypothesis (the most widely accepted) suggests that the adventitia of affected arteries contains undifferentiated mesenchymal cells, which do not migrate to the joints and secrete mucoid material into the vessel wall. The ganglion hypothesis proposes that adventitial cysts are composed of ectopic synovial ganglions, which migrated from the adjacent joint capsule into the adventitia. The microtraumatic theory

suggests that continuous movement of adjacent joints causes repetitive trauma to the vessels. The degenerative etiology suggests that myxomatous systemic degeneration from a generalized disorder causes cystic formation.

Digital subtraction angiography has been considered the gold standard for detection of CAD; however, color Doppler ultrasound, computed tomography angiography (CTA), and magnetic resonance angiography (MRA) have been proven to be useful diagnostic tools (5, 6).

Color Doppler ultrasound allows detecting an arterial stenosis or occlusion with surrounding cyst(s), which contain no flow and appear as anechoic or hypoechoic masses in the wall of the vessel.

The cysts can manifest as discrete stenosis of the vessel lumen on CTA (Fig. 1 and 2). If the cysts are concentric, the stenosis will have an "hourglass" appearance; if they are eccentric, the stenosis will manifest as classic "scimitar sign".

Cysts are hyperintense on T2-weighted magnetic resonance images (MRI) and have variable signal intensity on T1-weighted images because of the variable amount of mucoid material within the cysts (Fig. 3). Compression of the popliteal artery produced by cysts can be seen on axial MRI (Fig. 3) and MRA with three-dimensional "time-of-flight" imaging as "scimitar sign" (Fig. 4).

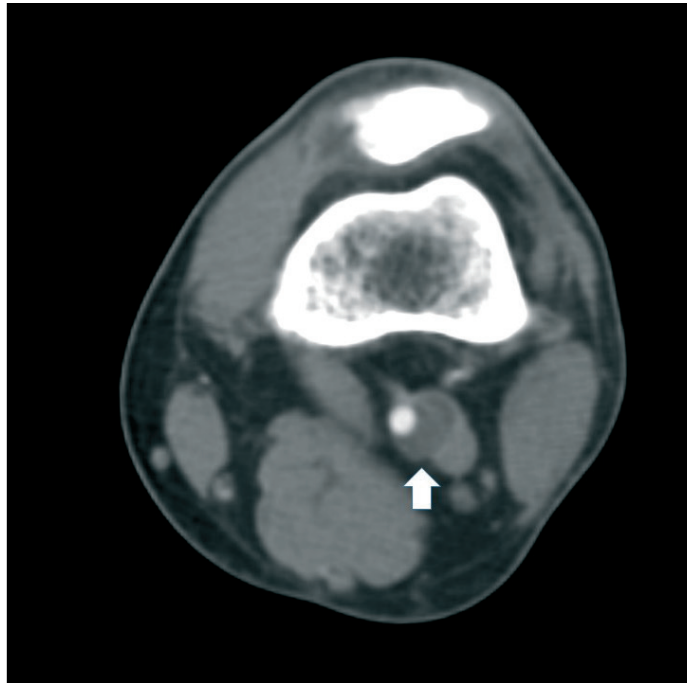


Figure 1. Cross-sectional computed tomography of 35-year-old male patient with complaints on intermittent claudication during routine walking demonstrates semi-circumferential cyst (arrow) within the wall of the left popliteal artery

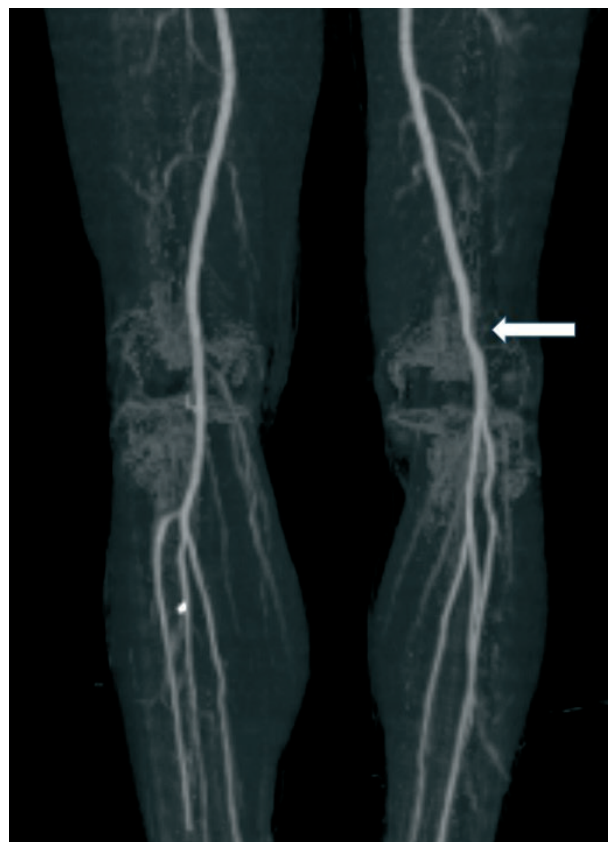


Figure 2. Computed tomography angiogram with "maximum intensity projection" technique of the same patient demonstrates an eccentric compression of the left popliteal artery by the cyst causing mild stenosis (arrow)

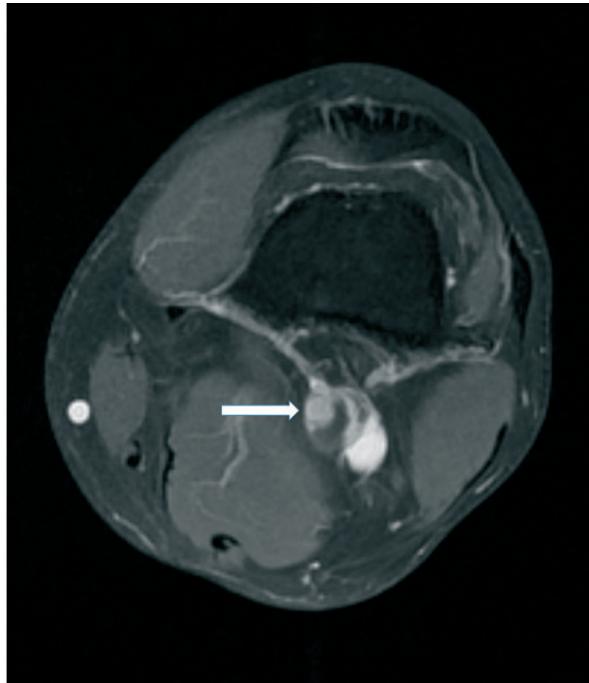


Figure 3. Cross-sectional T1-weighted magnetic resonance imaging of 37-year-old male patient with complaints on intermittent claudication during intensive exercise demonstrates multilocular hypointense cyst (arrow) within the wall of the left popliteal artery

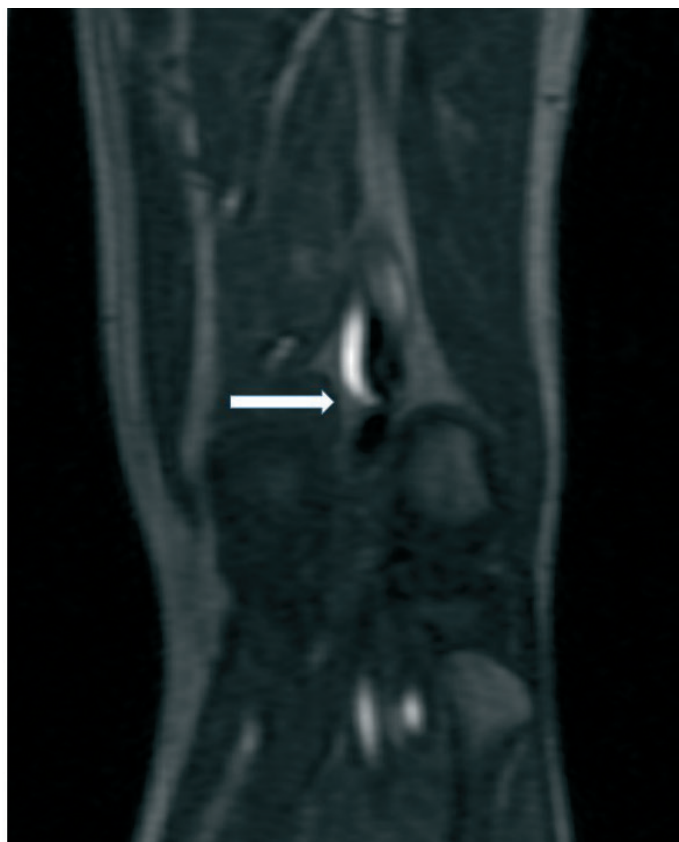

Figure 4. Magnetic resonance angiography of the same patient demonstrates mild lumen narrowing (arrow) of the popliteal artery due to the compression by the cyst from vascular wall

Management of CAD should be based on patient's clinical symptoms and radiologic findings. A conservative periodic observation is recommended for asymptomatic patients because spontaneous resolution of cystic lesions was reported (7). Percutaneous aspiration under ultrasound guidance may be performed; however, the cysts recurrence may occur (8). Percutaneous endovascular treatments such as balloon angioplasty and stent placement are often unsuccessful due to dense viscosity of the gelatinous cystic content (9). In cases of total occlusion, surgical treatment with resection and bypass is preferred, while excision of the cyst is preferred for artery stenosis (10).

In conclusion, cystic adventitial disease is a very rare vascular disorder that most frequently occurs in young or middle-aged male patients. In younger patients and in those without extensive atherosclerosis, the differential diagnosis of this disease must include also atherosclerosis, a pressure by neighboring muscles (so-called entrapment syndrome), aneurysm or cyst. Radiologic methods, especially cross-sectional magnetic resonance imaging and MRA, are important imaging tools for proper diagnosis and selecting the most appropriate treatment method.

Peer-review: Internal

Conflict of interest: None to declare

Authorship: K.A.

Acknowledgement and funding: None to declare

References

- Elias DA, White LM, Rubenstein JD, Christakis M, Merchant N. Clinical evaluation and MR imaging features of popliteal artery entrapment and cystic adventitial disease. *AJR Am J Roentgenol* 2003; 180: 627–32.
- Bascone C, Iqbal M, Narh-Martey P, Szuchmacher M, Cicchillo M, Krishnasastry KV. Venous adventitial cystic disease: a review of 45 cases treated since 1963. *Int J Vasc Med.* 2016; 2016:5287697. doi: 10.1155/2016/5287697.
- Paravastu SC, Regi JM, Turner DR. A contemporary review of cystic adventitial disease. *Vasc Endovasc Surg* 2012; 46: 5–14.
- Levien LJ, Benn CA. Adventitial cystic disease: a unifying hypothesis. *J Vasc Surg* 1998; 193-205. doi: 10.1016/s0741-5214(98)70155-7.
- Wright LB, Matchett WJ, Cruz CP. Popliteal artery disease: diagnosis and treatment. *Radiographics* 2004; 24: 467–79.
- Han SK, Park SW, Lee JW, Ahn SG, Youn YJ, Oh JR, et al. Intermittent claudication due to cystic adventitial disease of the popliteal artery: importance of multiple imaging modalities. *Korean Circ J* 2018; 48: 334-5. doi: 10.4070/kcj.2017.0319.
- Jibiki M, Miyata T, Shigematsu H. Cystic adventitial disease of the popliteal artery with spontaneous regression. *J Vasc Surg Cases Innov Tech* 2018; 4: 136-9. doi: 10.1016/j.jvscit.2018.01.006.
- Seo H, Fujii H, Aoyama T, Sasako Y. A case of adventitial cystic disease of the popliteal artery progressing rapidly after percutaneous ultrasound-guided aspiration. *Ann Vasc Dis* 2014; 7: 417-20. doi: 10.3400/avd.cr.14-00097.
- Wobig-Bittner R, Rua I, Pena C. Endovascular treatment of occlusive cystic adventitial disease. *J Vasc Interv Radiol* 2018; 29: 1624-6. doi: 10.1016/j.jvir.2018.06.025.
- Desy NM, Spinner RJ. The etiology and management of cystic adventitial disease. *J Vasc Surg* 2014; 60: 235-45, 245. e1-11. doi: 10.1016/j.jvs.2014.04.014.



Amphitheatre in Pamukkale, Turkey. Summer 2020. Yuriy Ivaniv, Lviv, Ukraine.