

QUIZ: ECHO IMAGING

Case

A 55 years old male patient with severe coronary artery disease was sent to our echocardiography lab for preoperative evaluation. Figure 1 and 2 were taken from his echo recordings (video 1 and 2). What is the differential diagnosis in such picture?

- A. A dilated aortic root
- B. A dilated coronary sinus with possible persistent left superior vena cava
- C. Ostium primum atrial septal defect
- D. A flail mitral valve

Zehra Ilke Akyildiz¹, Oben Baysan²

¹ Private Cardiology Clinic, İzmir, Turkey

² Guven Hospital, Ankara, Turkey

Peer-review: Internal and external

Conflict of interest: None to declare

Authorship: Z.I.A, O.B. are equally contributed to management of case and preparation of article

Acknowledgement and funding: None to declare

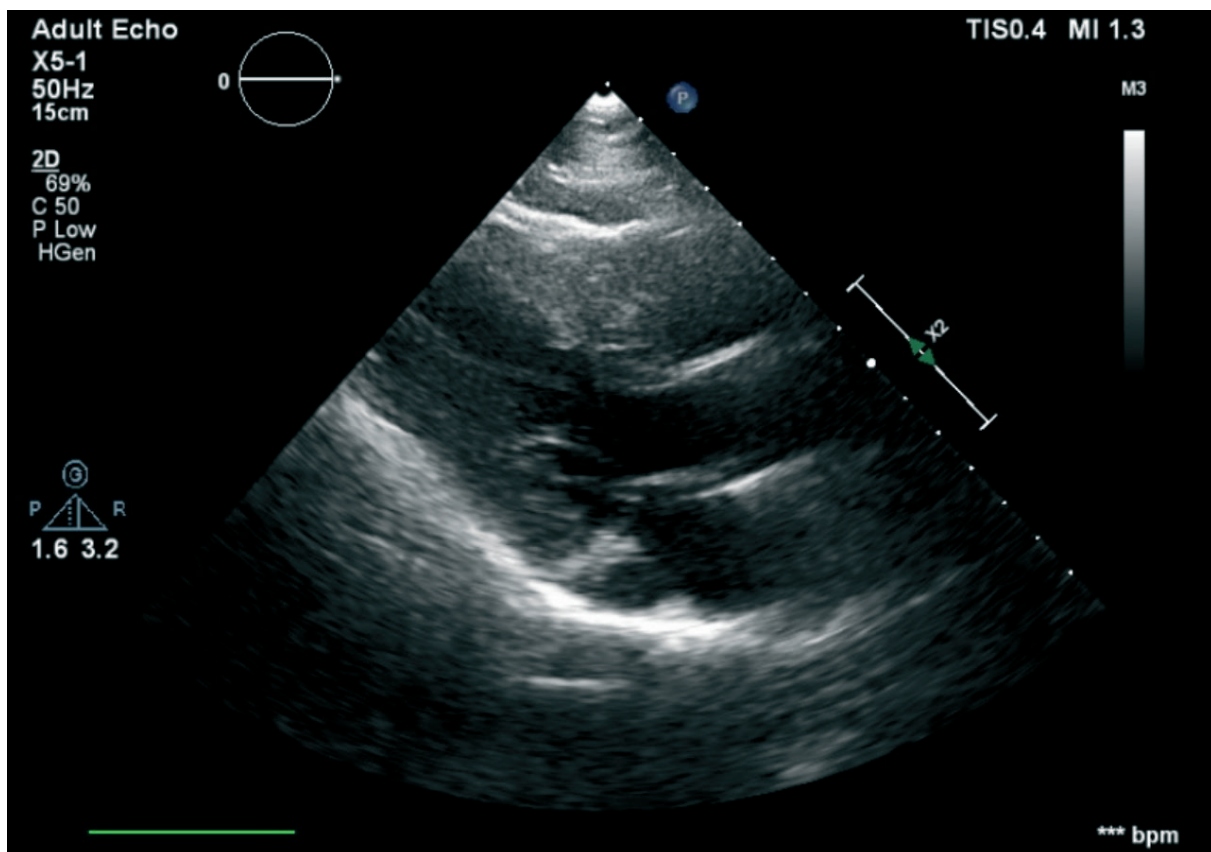


Figure 1. Echocardiographic image

Video 1. Echocardiographic images (visit www.hvt-journal.com to watch video)

Address for Correspondence: Zehra Ilke Akyildiz, Izmir, Turkey Email: ziakyildiz@hotmail.com

Received: 13.11.2020 Revised: 06.12.2020 Accepted: 06.12.2020

Copyright ©2020 Heart, Vessels and Transplantation

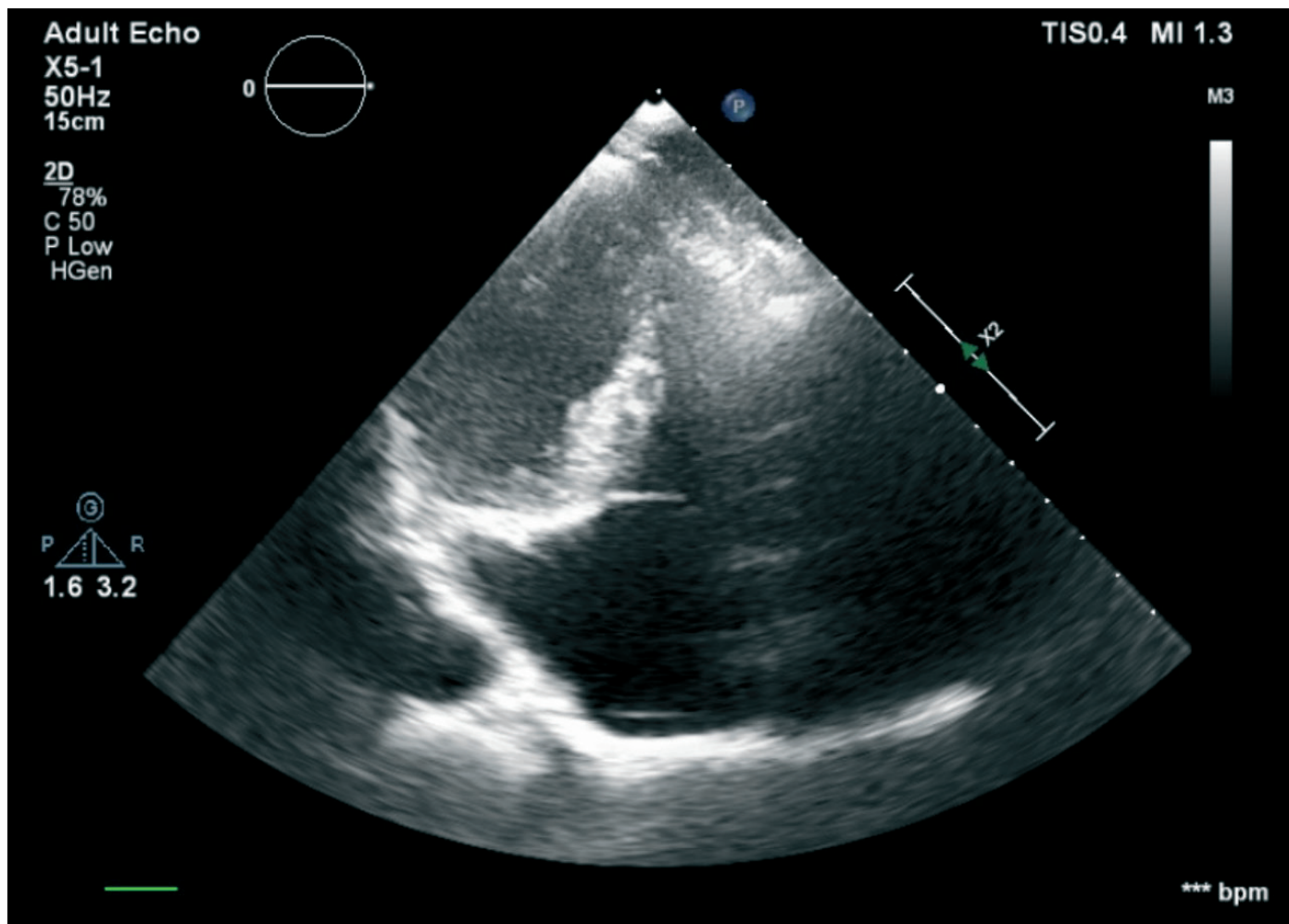


Figure 2. Echocardiographic image

Video 2. Echocardiographic images (visit www.hvt-journal.com to watch video)