

Quiz

Quiz: Electrocardiography

Female, 74 years, complains on “irregular heart beat”, episodic lightheadedness and lethargy.

A 7-lead Holter was recorded. Symptoms occurred in the evening hours while at rest, the corresponding

tracings are displayed in Figures 1 and 2. Speed of the recording – 25 mm/s.

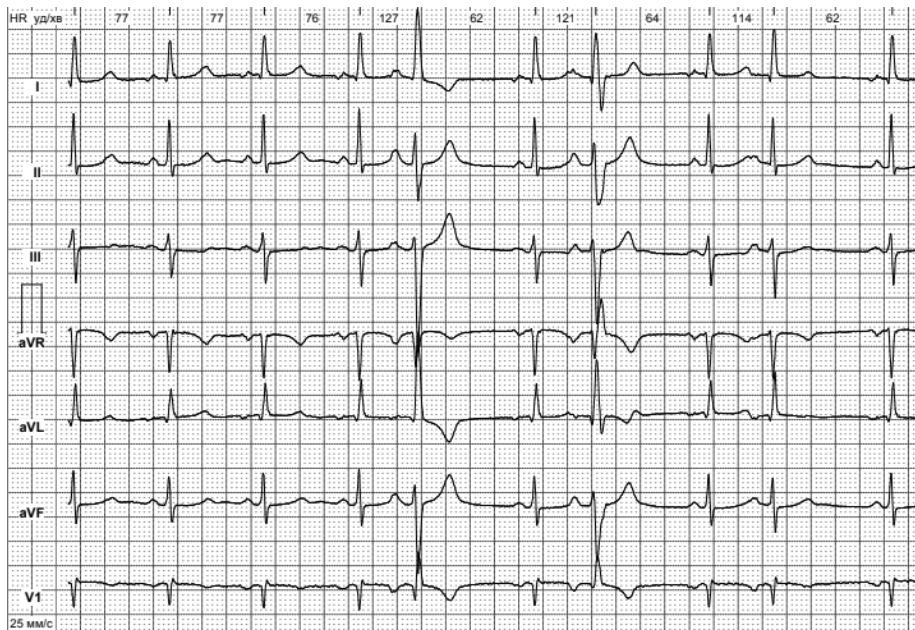


Figure 1. Electrocardiogram 1

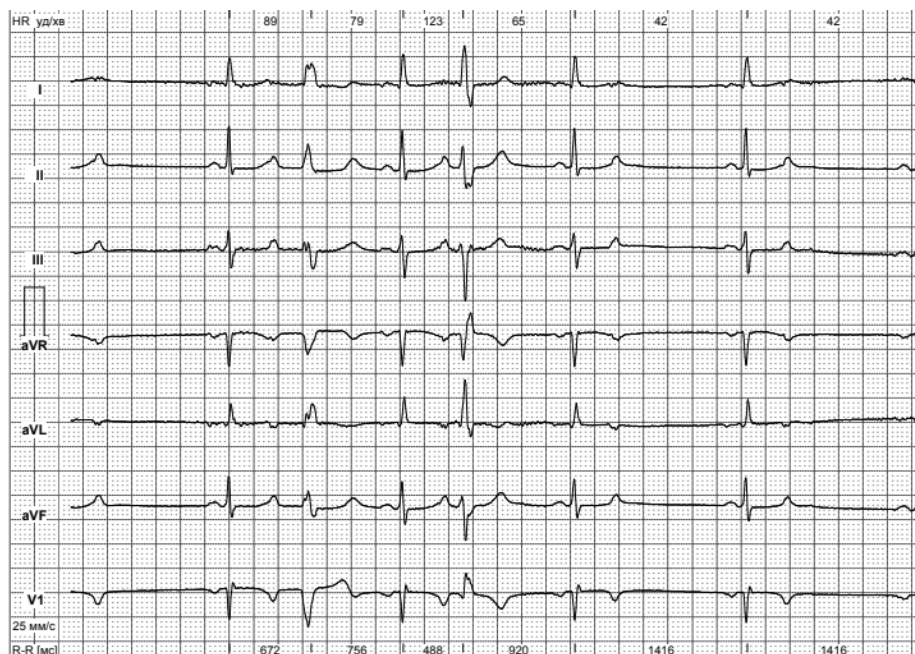


Figure 2. Electrocardiogram 2

Address for correspondence: Mykhaylo Sorokivskyy, Danylo Halytsky Lviv National Medical University, Ukraine

Phone: +380677837830 Email: msorokivskyy1@gmail.com

Received: 29.11.2020 Revised: 19.01.2021 Accepted: 20.01.2021

Copyright ©2021 Heart, Vessels and Transplantation

Doi: 10.24969/hvt.2021.239

Please chose ALL descriptions which can be detected on this ECG:

1. Sinus bradycardia
2. Sinoatrial block, second degree type II
3. Prolonged PQ interval
4. Multifocal ventricular extrasystoles
5. Atrial bigeminy
6. Ventricular bigeminy
7. Blocked atrial extrasystoles
8. Aberrant conduction
9. Tachycardia-bradycardia syndrome
10. AV block II

Mykhaylo Sorokivskyy, Rostyslav Kovalchuk,
Volodymyr Kulish
Danylo Halytsky Lviv National Medical University, Lviv.
Ukraine

Ethics : A patient's consent was obtained for all procedures.

Peer-review: Internal and external

Conflict of interest: None to declare

Authorship: M.S., R.K., V.K. equally contributed to preparation of manuscript and fulfilled authorship criteria

Acknowledgement and funding: None to declare



Ala-Archa gorge, 2020. Aliya Kadyrova, Bishkek, Kyrgyzstan

