

Quiz

Quiz: Echo imaging case

A 78 years old female patient with arterial hypertension controlled by lisinopril and amlodipine combination having non-specific chest pain and episodes of palpitation has been examined in our echocardiography laboratory. She has undergone right sided nephrectomy because of renal carcinoma 15 years ago with no chemotherapy after. Figure 1 was taken from her echo recording. Her heart chambers had normal size. No deterioration of left ventricular contractility. Mild mitral regurgitation and

restrictive type of diastolic transmitral flow. No Echo-signs of pulmonary hypertension revealed. No pericardial fluid.

What is the most probable diagnosis in this case?

- A. Metastatic LV tumor.
- B. Malignant myocardial tumor.
- C. Lipoma of the LV located on the mitral annulus.
- D. Caseous calcification of MV annulus.
- E. Mitral annular abscess.

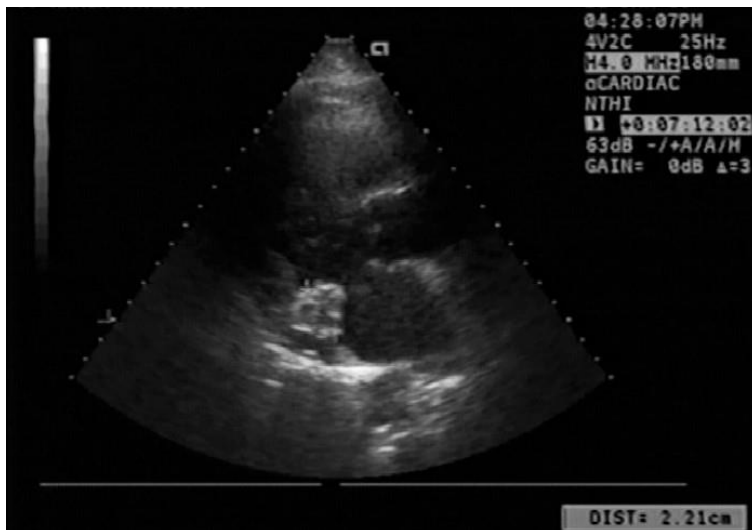


Figure 1. Echocardiographic image. Parasternal long-axis view.

Yuriy Ivaniv, Natalia Lozynska, Ihor Ivaniv
Diagnostic Radiology Department, Danylo Halytsky Medical University, Lviv, Ukraine

Ethics: informed consent was obtained from a patient before call procedures and treatment

Peer-review: External and internal

Conflict of interest: None to declare

Authorship: Y.I., N.L. and I.I. equally contribute to the preparation of manuscript and fulfilled all authorship criteria

Acknowledgments and funding: None to declare

Address for Correspondence: Yuriy Ivaniv, Diagnostic Radiology Department, Danylo Halytsky Medical University, Lviv, Ukraine

Received: 15.05.2021 **Revised:** 07.06.2021 **Accepted:** 07.06.2021

Copyright ©2021 Heart, Vessels and Transplantation

doi: 10.24969/hvt.2020.255