

Case report

A case of undifferentiated pleomorphic cardiac sarcoma

Sergey Yakovlev¹, Anna Kalinskaya²

¹Moscow City hospital named after I.V. Davidovsky, Moscow, Russian Federation

²Moscow State University of Medicine and Dentistry, Moscow, Russian Federation

Abstract

Primary cardiac sarcoma is known to have a poor prognosis due to late presentation, multiple metastases, and complications, challenging treatment options. We present a case of a 78-year-old female patient who was admitted to our hospital with progressive dyspnea and chest pain. Echocardiography revealed multiple masses of different shape and size in the left atrium, the left and right ventricles. Cardiac magnetic resonance confirmed multiple cardiac masses with signs of invasion in the myocardium and heterogeneous late gadolinium enhancement in all these masses. A biopsy of the abdominal mass revealed an undifferentiated pleomorphic sarcoma.

We planned chemotherapy and supportive measures. Before the initiation of the chemotherapy, the clinical situation worsened dramatically. Despite the pericardiocentesis, the patient died due to cardiac tamponade. An autopsy revealed a massive tumor in the interatrial septum and multiple metastases in both ventricles, lungs, and abdomen.

Key words: cardiac sarcoma, left atrium, left ventricle, right ventricle, metastases, echocardiography, cardiac magnetic resonance, biopsy, autopsy, tamponade

(Heart Vessels Transplant 2021; 5; doi: 10.24969/hvt.2020.263)

Introduction

Primary cardiac tumors are uncommon (1-3). In case of primary cardiac tumor we should pay special attention to the evaluation of the malignancy (it can be found in 25% of cases). The most common malignant tumor is sarcoma. Primary cardiac sarcoma is known to have poor prognosis due to late presentation, multiple metastases and complications, challenging treatment options (4). The most common cause of death in these patients is heart failure (5).

We present a case of undifferentiated pleomorphic cardiac sarcoma that was complicated by cardiac tamponade. The patient died due to cardiac tamponade.

Case report

A 78-year-old female patient was admitted to our hospital with progressive dyspnea and chest pain,

which occurred during minimal physical activity (chronic heart failure NYHA functional class III). She had been diagnosed with hypertension stage 2, diabetes mellitus type 2 several years ago. One year ago, she noticed the dyspnea and chest pain during physical activity. Two months ago, she had an episode of palpitation. The electrocardiography (ECG) revealed atrial fibrillation. Her sinus rhythm was restored with amiodarone. The echocardiography revealed an echogenic mass in left atrium. The myxoma was suspected. Coronary angiography was performed to exclude coronary artery disease. It revealed absolutely normal coronary arteries.

Upon admission, vital signs were unremarkable. The complete blood count revealed hypochromic anemia (hemoglobin, 94 g/L; red blood cell count 3.55×10^{12} /L).

Address for Correspondence: Sergey Yakovlev, Moscow City hospital named after I.V. Davidovsky, Moscow, Russian Federation, Email: dr.s.yakovlev@gmail.com Mobile: +79161884244

Received: 02.07.2021 Revised: 10.08.2021 Accepted: 10.08.2021

Copyright ©2021 Heart, Vessels and Transplantation

A round-shaped mass of 1.5 to 2 cm in diameter was palpated at the anterior abdominal wall (mesogastrium). An ECG upon admission to our clinic was normal. Two-dimension echocardiography revealed multiple masses of different shape and size in the left atrium, the left and right ventricles. The left ventricle ejection fraction was 60–65%; a restrictive type of diastolic dysfunction was observed

(Video 1, 2, Fig. 1. Watch videos at www.hvt-journal.com). Cardiac magnetic resonance (CMR) confirmed multiple cardiac masses with signs of invasion in the myocardium and heterogenous late gadolinium enhancement (LGE) in all these masses (Video 3, 4, Fig. 2 Watch videos at www.hvt-journal.com).

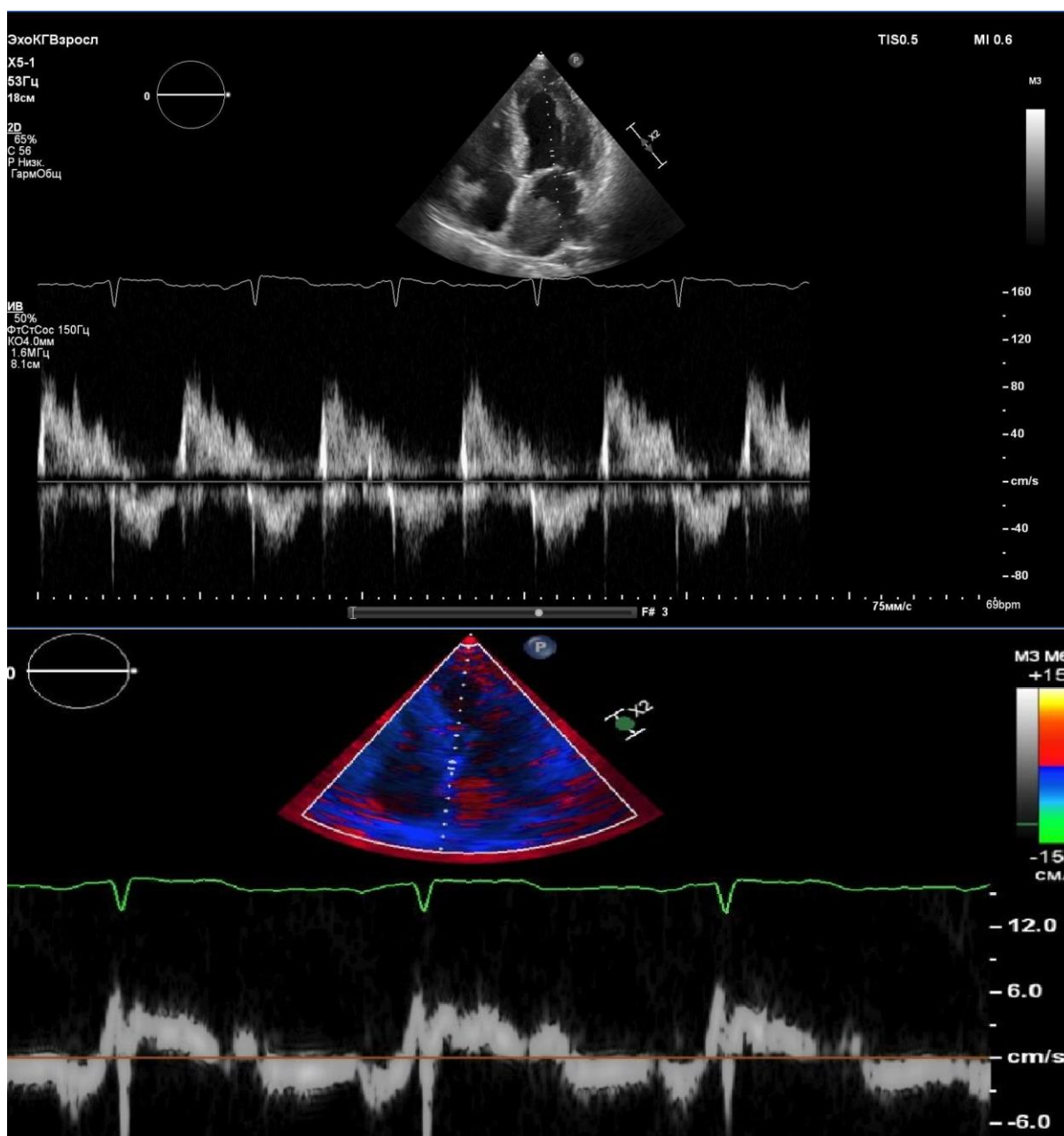


Figure 1. Upper part of the figure- transmitral flow, pulsed wave Doppler. Lower part of the figure- tissue Doppler image of restrictive pattern of transmitral and mitral annular flow.

Video 1. Echocardiography. Apical four-chamber view. Multiple masses in left atrium, left ventricle and right ventricle.

Video 2. Echocardiography. Parasternal long-axis view. Multiple masses in left atrium and left ventricle.

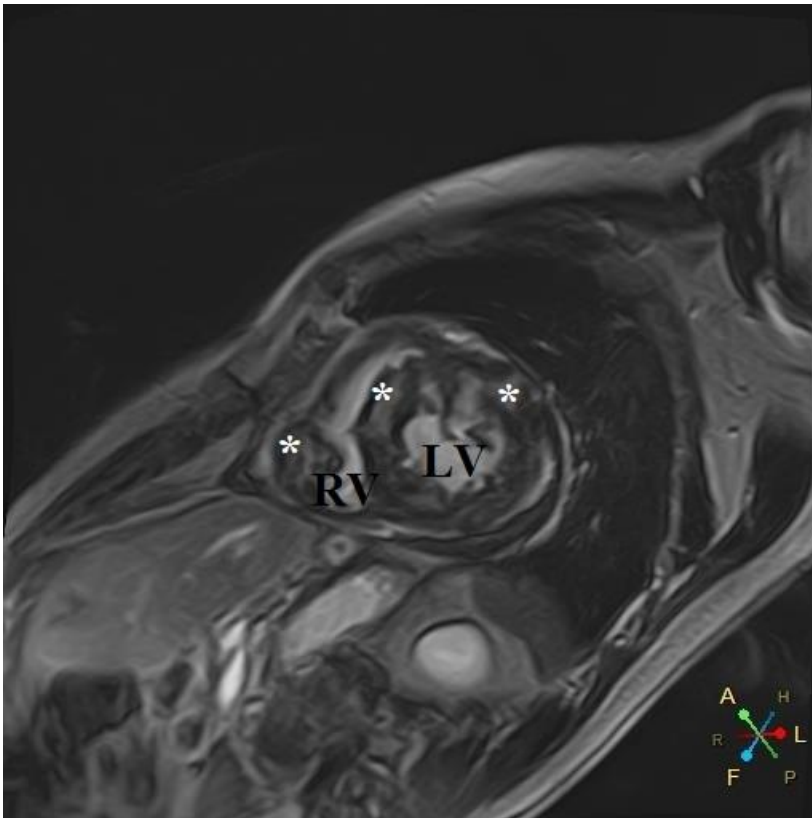


Figure 2. Cardiac magnetic resonance imaging - short axis view of intramyocardial masses with late gadolinium enhancement (*). LV – left ventricle, RV – right ventricle

Video 3. Cardiac magnetic resonance imaging. Four-chamber view. Multiple masses in left atrium, left ventricle and right ventricle

Video 4. Cardiac magnetic resonance imaging. Short-axis view. Multiple masses in left ventricle and right ventricle

A biopsy of the abdominal wall mass was performed. It revealed a low-differentiated malignant tumor. Immunohistochemistry assay confirmed an undifferentiated pleomorphic sarcoma. Figure 3 showed the microscopic appearance of the heart tumor, composed of spindle cells admixed with

polygonal or rounded cells, scattered bizarre cells, arranged in a storiform pattern. There were marked cellularity and nuclear pleomorphism with abundant atypical mitoses. Figure 4 showed marked proliferation activity of tumor cells, labeled with Ki67.

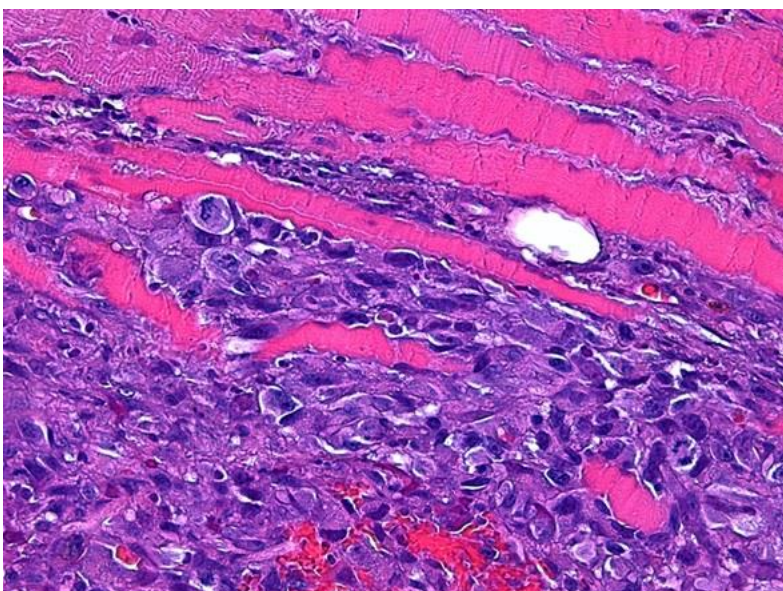


Figure 3. Hematoxylin and eosin stain, magnification 400 – image of heart tumor (See explanation in text).

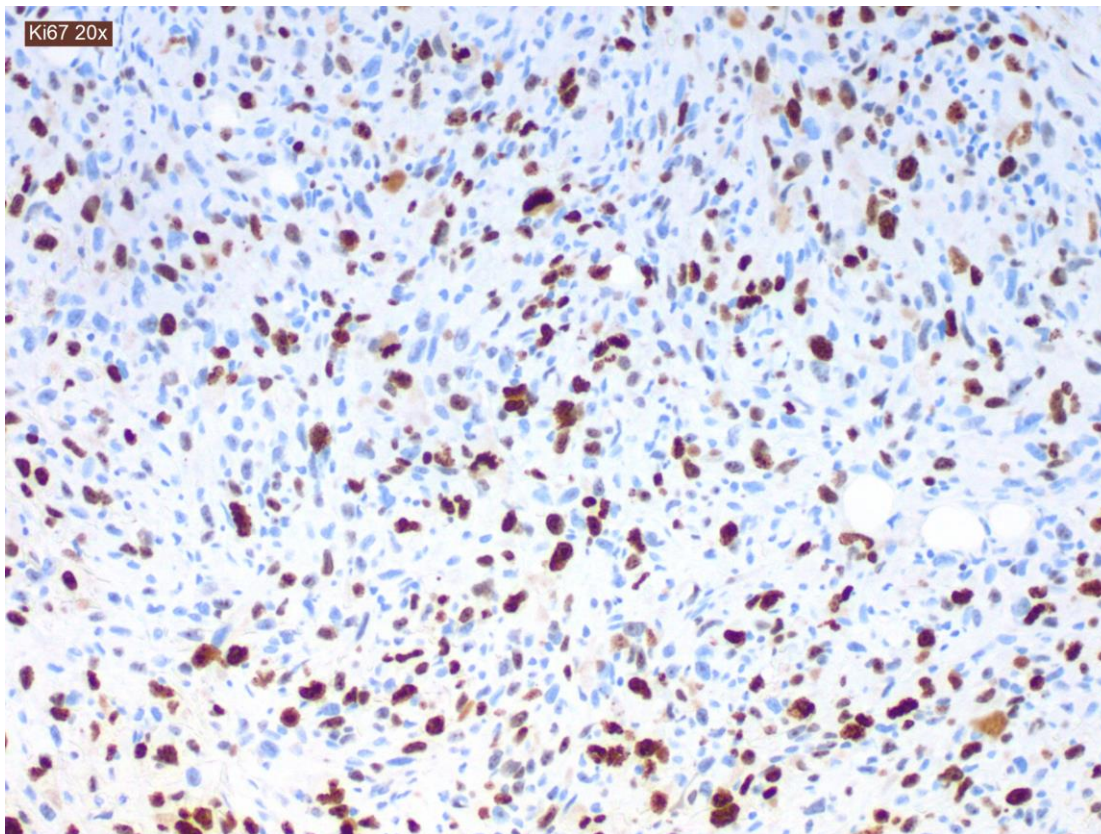


Figure 4. Immunohistochemistry assay, magnification 200 - image of heart tumor (See explanation in text).

Because of the extent of the lesion site (left atrium and both ventricles), the only options for treatment were chemotherapy and supportive measures. Before the initiation of the chemotherapy, the clinical situation worsened dramatically. After the initial episode of severe dyspnea, the patient lost consciousness. The emergency echocardiography showed signs of cardiac tamponade. Despite the pericardiocentesis, the patient died.

An autopsy revealed a massive tumor in the interatrial septum and multiple metastases in both ventricles, lungs, and abdomen (Fig. 5).

Discussion

Primary malignant heart tumors are rare conditions (1-3). Undifferentiated pleomorphic sarcoma (UPS) occurs in 12% cases of primary cardiac sarcoma (6). It is known to be a high-grade malignancy that proliferates rapidly. The median survival time is about 6-12 months (7). The mean age of UPS is known to be about 45 years (8). This case is unusual due to the very late occurrence and clinical presentation of the tumor.

UPS can cause different symptoms such as dyspnea, palpitations, or weakness. In some cases, the first

presentations of the tumor can be arrhythmia, i.e. atrial fibrillation, or acute decompensation of patient status (i.e. acute heart failure, life-threatening arrhythmias or tamponade) (9). All these signs and symptoms are not specific. Sometimes UPS can be an accidental finding on echocardiography, computed tomography scan or CMR. In our case the patient had complex clinical presentation: dyspnea, chest pain and atrial fibrillation. Dyspnea and atrial fibrillation in our patient can be caused by diastolic dysfunction of left ventricle due to sarcoma invasion or mitral valve, and pulmonary veins obstruction.

The best treatment strategy is a combination of complete surgical excision, chemotherapy and radiotherapy (10). But UPS is a locally invasive tumor. This makes complete surgical excision often impossible. Even after the complete tumor removal, the relapse rate is very high (11). Heart or heart-lung transplantation can be an option, but this procedure does not significantly change survival and often has a high risk (12, 13). There are no exact protocols for chemotherapy and radiotherapy in such a case, different combinations can be used (14).

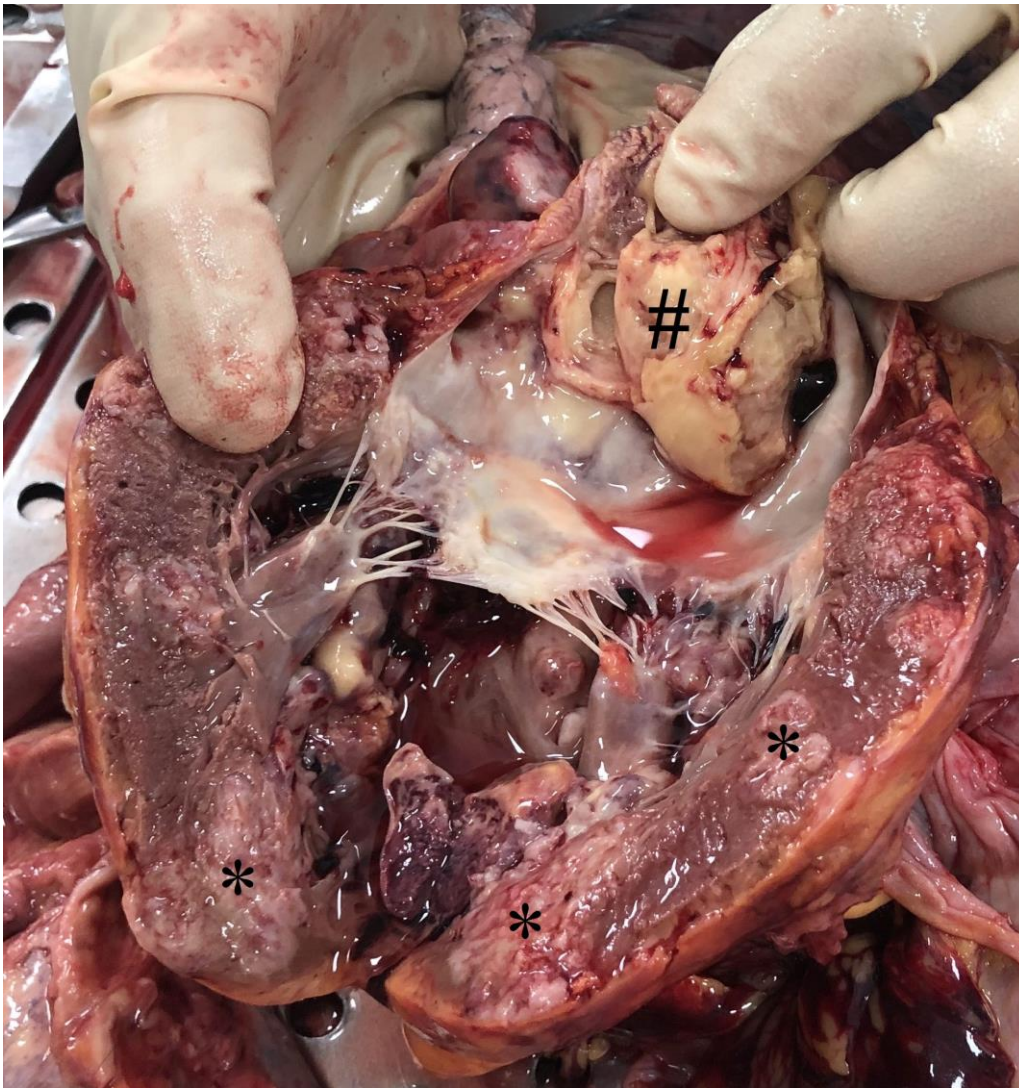


Figure 5. Autopsy. Opened left ventricle and left atrium. # - mass in the left atrium, * - intramyocardial metastases in left ventricular wall

Our patient had a grave prognosis as she had multiple intracardiac and extracardiac metastases that made the surgical excision and heart transplantation unsuitable. Thus, we planned to perform chemotherapy. Unfortunately, the patient developed the acute cardiac tamponade that led to the death despite the pericardiocentesis. The acute cardiac tamponade is an extremely dangerous condition that can be caused by different reasons: cardiac muscle rupture due to myocardial infarction; coronary artery perforation, systemic disease and etc. The cardiac tumors should also be under the consideration.

Conclusion

Undifferentiated pleomorphic sarcoma is an extremely rare disease. Presentation of UPS can be different: from silent cases with accidental findings to acute deterioration (heart failure, arrhythmias, cardiac tamponade). Treatment is challenging and prognosis is often poor. The preferable treatment option is a combination of surgery, chemotherapy and radiotherapy.

Ethics: Informed consent and permission of patient was obtained for all procedures

Peer-review: External and internal

Conflict of interest: None to declare

Authorship: S.Y. and A.K. are equally contributed to case management and preparation of article

Acknowledgments and funding: None to declare

References

- 1.Reynen K. Frequency of primary tumors of the heart. *Am J Cardiol* 1996; 77: 107.
- 2.Nomoto N, Tani T, Konda T, Kim K, Kitai T, Ota M, et al. Primary and metastatic cardiac tumors: echocardiographic diagnosis, treatment and prognosis in a 15-years single center study. *J Cardiothorac Surg* 2017; 12: 103.
- 3.Cresti A, Chiavarelli M, Glauber M, Tanganelli P, Scalese M, Cesareo F, et al. Incidence rate of primary cardiac tumors: a 14-year population study. *J Cardiovasc Med* 2016; 17: 37-43.
- 4.Brittany LS, Zhao L, Leja M, McHugh JB, Shango MM, Baker LH, et al. Primary cardiac sarcoma: a rare, aggressive malignancy with a high propensity for brain metastases. *Sarcoma* 2019; 1960593
- 5.Donsbeck WK, Ranchere D, Coindre JM, Le Gall F, Cordier JF, Loire R. Primary cardiac sarcomas: an immunohistochemical and grading study with long-term follow-up of 24 cases. *Histopathology* 1999; 34: 295–304.
- 6.Randhawa JS, Budd GT, Randhawa M, Ahluwalia M, Jia X, Daw H. Primary cardiac sarcoma: 25-year Cleveland Clinic experience. *Am J Clin Oncol* 2016; 39: 593–9.
- 7.Vallés-Torres J, Izquierdo-Villarroya MB, Vallejo-Gil JM, Casado-Domínguez JM, Roche Latasa AB, Auquilla-Clavijo P. Cardiac undifferentiated pleomorphic sarcoma mimicking left atrial myxoma. *J Cardiothorac Vasc Anesth* 2019; 33: 493-6.
- 8.Oliveira GH, Al-Kindi SG, Hoimes Ch, Park SJ. Characteristics and survival of malignant cardiac tumors. A 40-year analysis of >500 patients. *Circulation* 2015; 132: 2395–402.
- 9.Kim DM, Hong JH, Kim SY, Yoo KD, Seo JY, Rhee KJ, et al. Primary cardiac angiosarcoma presenting with cardiac tamponade. *Korean Circ J* 2010; 40: 86–9.
- 10.Kong PK, Theodorou S, Beran E, Singh H, Dimitri W. Primary cardiac undifferentiated sarcoma of the right atrium presenting with cardiac tamponade. *Cardiovasc Pathol* 2009; 18: 110-3.
- 11.Truong PT, Jones SO, Martens B, Alexander C, Paquette M, Joe H, et al. Treatment and outcomes in adult patients with primary cardiac sarcoma: the British Columbia Cancer Agency experience. *Ann Surg Oncol* 2009; 16: 3358.
- 12.Li H, Yang S, Chen H, Yang Zh, Hong T, Hou Y, et al. Survival after heart transplantation for non-metastatic primary cardiac sarcoma. *J Cardiothorac Surg* 2016; 11: 145.
- 13.Mazuecos MJ, Manso RF, Cubero JS, Ramos JT, Domínguez JFO, Rivera LAP. Is heart transplantation for primary cardiac sarcoma a useful therapeutic option? *Rev Esp Cardiol* 2003; 56: 408-11.
14. Patrikidou A, Domont J, Cioffi A, Le Cesne A. Treating soft tissue sarcomas with adjuvant chemotherapy. *Curr Treat Options Oncol* 2011; 12: 21-31.



Amsterdam, The Netherlands – March 2021. Jonathan Lipton, Melbourne, Hobart, Tasmania, Australia