

## Quiz

### Multimodality imaging of a left ventricular mass

**Key words:** intracardiac mass, echocardiography, cardiac magnetic resonance, multimodality imaging

#### Presentation

A 65-years old male patient was admitted to the clinic due to exertional dyspnea and palpitation. He had atrial fibrillation for last 18 months, had no previous history of coronary artery disease or chest pain, no embolic events, no fever, dental procedures or antibiotic therapy for last three months. Patient has arterial hypertension with maximal pressure 200/100 mm Hg, he is smoker and he has chronic obstructive pulmonary disease. Blood tests were normal.

ECG revealed atrial fibrillation. Echocardiography (ECHO) (Phillips Epiq 7, Andover, Massachusetts, USA) (video 1, video 2, video 3, video 4) was performed.

Video 1. Apical 4-chamber echo view

Video 2. Apical 3-chamber echo view

Video 3. Zoomed apex of the left ventricle

Video 4. Zoomed apex of the left ventricle with color Doppler

Which abnormality do you see?

- A. Decreased left ventricular ejection fraction (LVEF) and additional mass in left ventricle cavity
- B. Normal LVEF and additional mass in left atrium
- C. Normal LVEF and mitral stenosis
- D. Decreased LVEF and wall motion abnormalities
- E. LV myocardial noncompaction and additional mass in left ventricle cavity

To clarify the observed ECHO findings the cardiac magnetic resonance imaging (CMR) with gadolinium was performed (Figures 1-3).

What suggestion can be done combining ECHO and CMR?

- A. Benign cardiac tumor in LV cavity
- B. LV myocardial noncompaction and thrombus
- C. Myocardial infarction and thrombus
- D. Malignant cardiac tumor in LV cavity

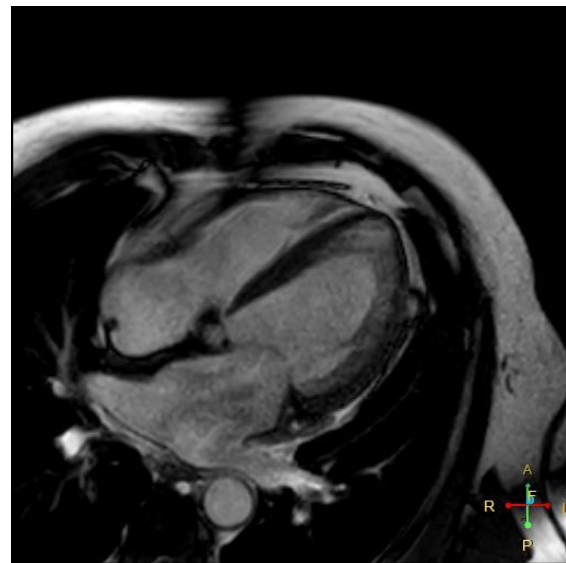


Figure 1. A 4-chamber view CMR  
CMR - cardiac magnetic resonance imaging

---

**Address for correspondence:** Sergey Yakovlev, Moscow City hospital named after I.V. Davidovsky, Moscow, Russian Federation **Email:** [dr.s.yakovlev@gmail.com](mailto:dr.s.yakovlev@gmail.com) **Mobile:** +79161884244

**Received:** 15.09.2021 **Revised:** 21.10.2021 **Accepted:** 21.10.2021

**Copyright ©2021 Heart, Vessels and Transplantation**

**Doi: 10.24969/hvt.2021.278**

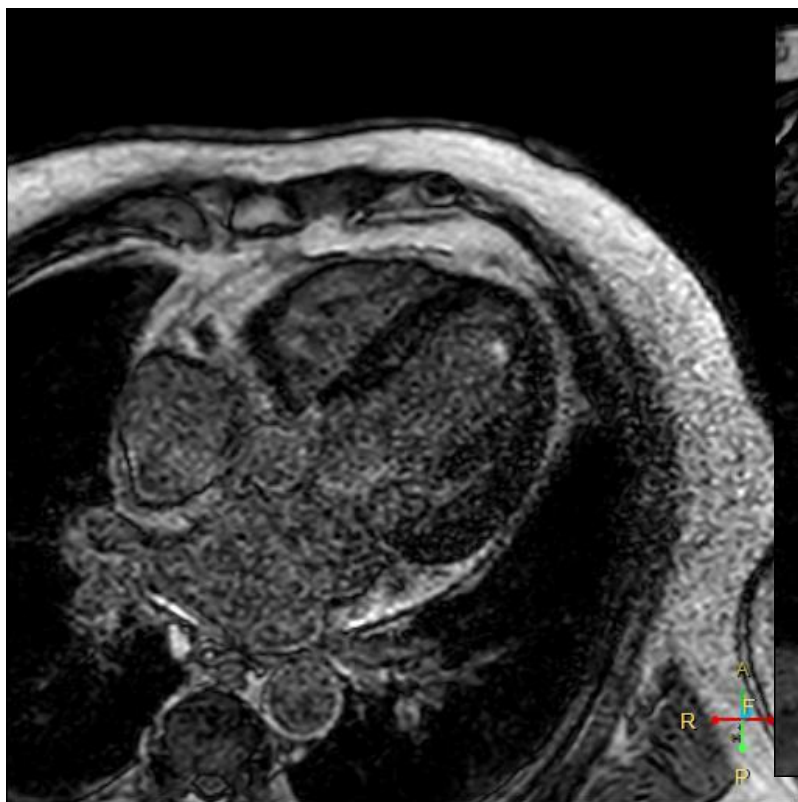


Figure 2. A 4-chamber view LGE CMR  
CMR - cardiac magnetic resonance imaging, LGE - late gadolinium enhancement

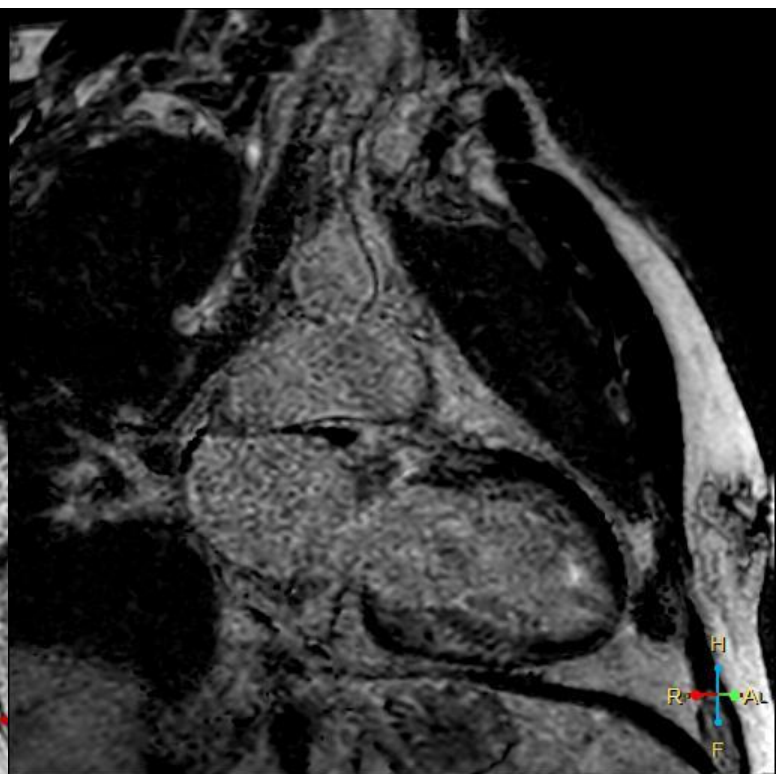


Figure 3. A 2-chamber view LGE CMR  
CMR - cardiac magnetic resonance imaging, LGE - late gadolinium enhancement

Sergey Yakovlev<sup>1</sup>, Anna Kalinskaya<sup>2</sup>,

<sup>1</sup>Moscow City hospital named after I.V. Davidovsky,  
Moscow, Russian Federation

<sup>2</sup>Moscow State University of Medicine And Dentistry,  
Moscow, Russian Federation

**Conflict of interest:** None to declare

**Peer-review:** Internal and external

**Authorship:** S.Y. and A.K. are equally contributed to  
preparation of manuscript and fulfilled authorship  
criteria

**Acknowledgement and funding:** None to declare