

Quiz: Multimodality imaging of a left ventricular mass

Key words: intracardiac mass, echocardiography, cardiac magnetic resonance, multimodality imaging

Presentation

A 65 years old male patient was admitted to the clinic due to exertional dyspnea and palpitation. He had atrial fibrillation for last 18 months, had no previous history of coronary artery disease or chest pain, no embolic events, no fever, dental procedures or antibiotic therapy for last three months. Patient has arterial hypertension with maximal pressure 200/100 mm Hg, he is smoker and he has chronic obstructive pulmonary disease. Blood tests were normal.

Electrocardiogram revealed atrial fibrillation. Echocardiography (ECHO) (Phillips Epiq 7, Andover, Massachusetts, USA) (video 1, video 2, video 3, video 4) was performed.

Video 1. Apical 4-chamber echo view

Video 2. Apical 3-chamber echo view

Video 3. Zoomed apex of the left ventricle

Video 4. Zoomed apex of the left ventricle with color Doppler
(Watch videos at www.hvt-journal.com)

Which abnormality do you see?

- A. Decreased left ventricular ejection fraction (LVEF) and additional mass in left ventricle cavity
- B. Normal LVEF and additional mass in left atrium
- C. Normal LVEF and mitral stenosis
- D. Decreased LVEF and wall motion abnormalities
- E. LV myocardial noncompaction and additional mass in left ventricle cavity

To clarify the observed ECHO findings the cardiac magnetic resonance imaging (CMR) with gadolinium was performed (Fig. 1-3).

What suggestion can be done combining ECHO and CMR?

- A. Benign cardiac tumor in LV cavity
- B. LV myocardial noncompaction and thrombus
- C. Myocardial infarction and thrombus
- D. Malignant cardiac tumor in LV cavity

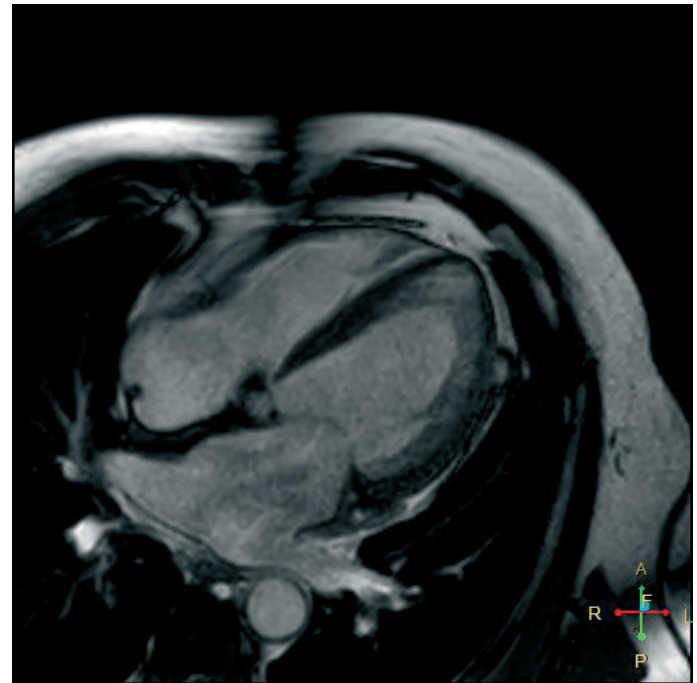


Figure 1. A 4-chamber view CMR
CMR - cardiac magnetic resonance imaging

Address for correspondence: Sergey Yakovlev, Moscow City hospital named after I.V. Davidovsky, Moscow, Russian Federation
Email: dr.s.yakovlev@gmail.com Mobile: +79161884244

Received: 15.09.2021 **Revised:** 21.10.2021 **Accepted:** 21.10.2021

Copyright ©2021 Heart, Vessels and Transplantation

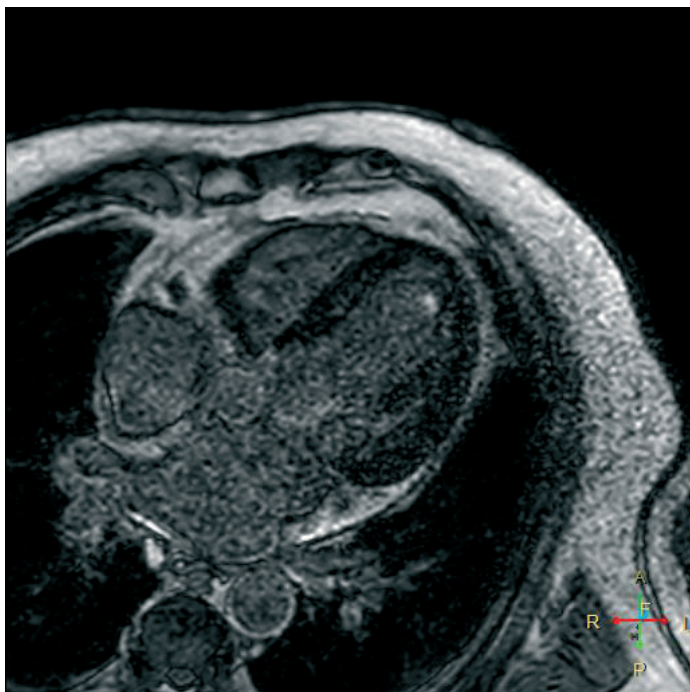


Figure 2. A 4-chamber view LGE CMR

CMR - cardiac magnetic resonance imaging, LGE - late gadolinium enhancement

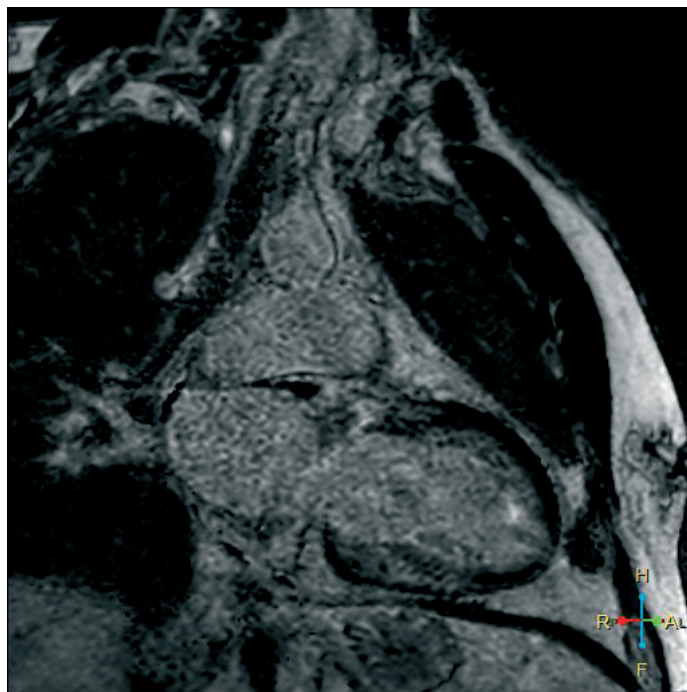


Figure 3. A 2-chamber view LGE CMR

CMR - cardiac magnetic resonance imaging, LGE - late gadolinium enhancement

Sergey Yakovlev¹, Anna Kalinskaya²

¹ Moscow City hospital named after I.V. Davidovsky, Moscow, Russian Federation

² Moscow State University of Medicine And Dentistry, Moscow, Russian Federation

Ethics: Informed consent was obtained from patient before all procedures

Peer-review: Internal and external

Conflict of interest: None to declare

Authorship: S.Y. and A.K. are equally contributed to preparation of manuscript and fulfilled authorship criteria

Acknowledgement and funding: None to declare