

Magnetic resonance imaging as a tool to examine the brain pathology

1. Which method of magnetic resonance (MR) imaging is indicated in the given image?

- a) Diffusion-weighted imaging (DWI)
- b) MR spectroscopy
- c) MR arteriography
- d) MR venography

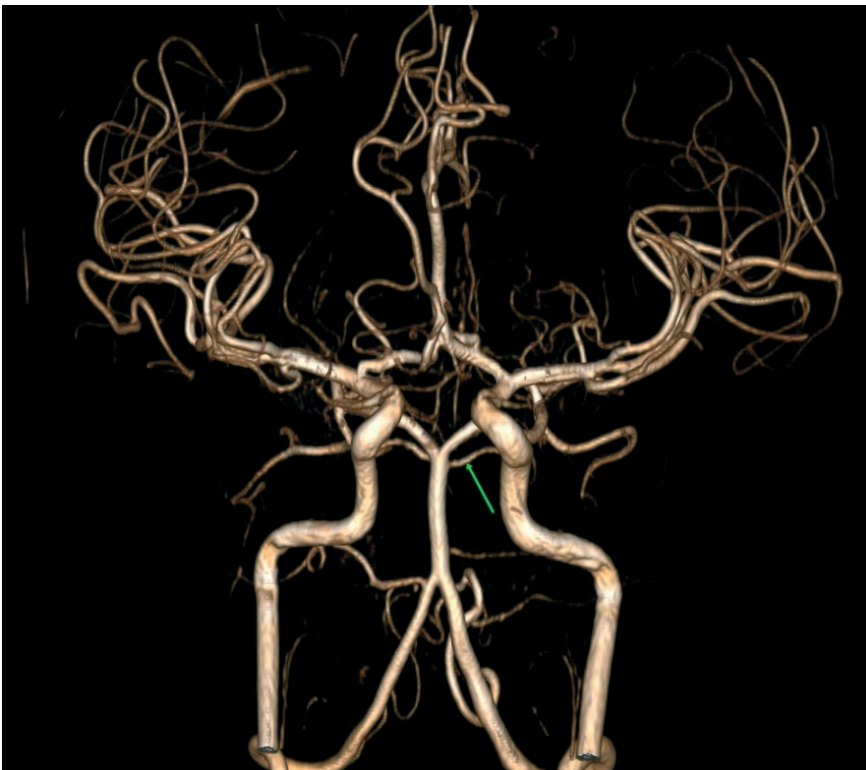

Figure 1. Magnetic resonance imaging image

Address for Correspondence: Aliya Kadyrova, Department of Radiology, I.K. Akhunbaev Kyrgyz State Medical Academy, 92A, Akhunbaev str., 720020, Bishkek, Kyrgyz Republic Email: al-kadyrova@yandex.ru

Received: 03.02.2022 **Revised:** 20.02.2022 **Accepted:** 21.02.2022

Copyright ©2022 Heart, Vessels and Transplantation

2. A patient with a hemorrhagic stroke. Determine the stage of the hematoma:

- a) Hyperacute
- b) Acute
- c) Subacute
- d) Chronic

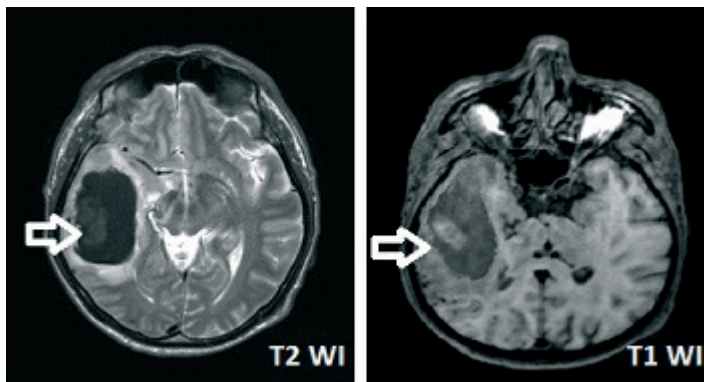


Figure 2. Magnetic resonance imaging image

3. Which method of investigation is shown in the image?

- a) MR tractography
- b) MR spectrography
- c) MR perfusion
- d) Functional MRI

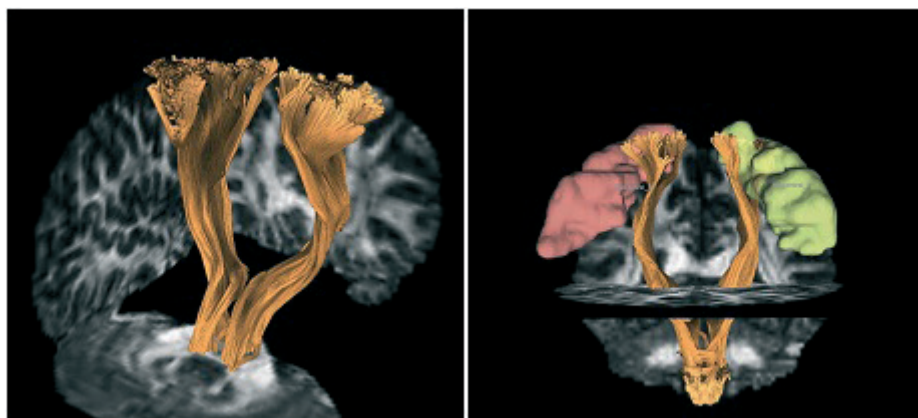


Figure 3. Magnetic resonance imaging image

4. Identify the investigation method used in the given image below?

- a) Contrast-enhanced MRI
- b) Brain MRI
- c) MR spectrography
- d) MR perfusion

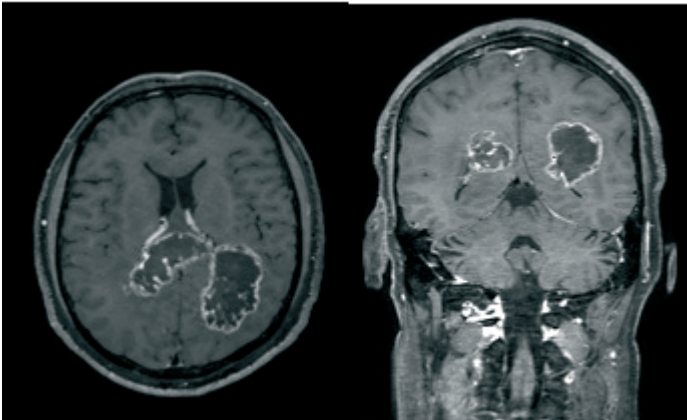


Figure 4. Magnetic resonance imaging image

5. Identify the pathology shown in the given image below:

- a) Corpus callosum agenesis
- b) Hypoplasia of the corpus callosum
- c) Pericallosal lipoma of corpus callosum
- d) Normal MRI scan

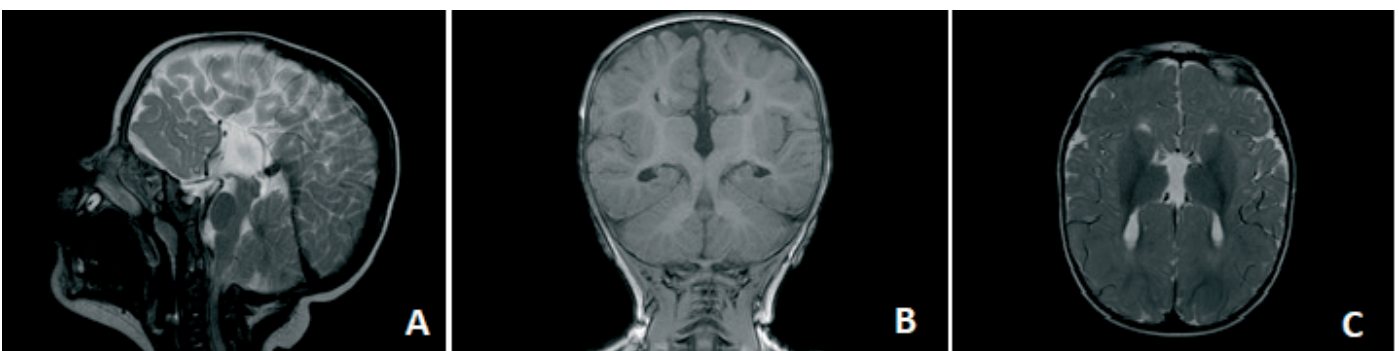


Figure 5. Magnetic resonance imaging image

6. Which method of investigation is used in the given image?

- a) Contrast-enhanced MRI
- b) MRI spectroscopy
- c) Tractography

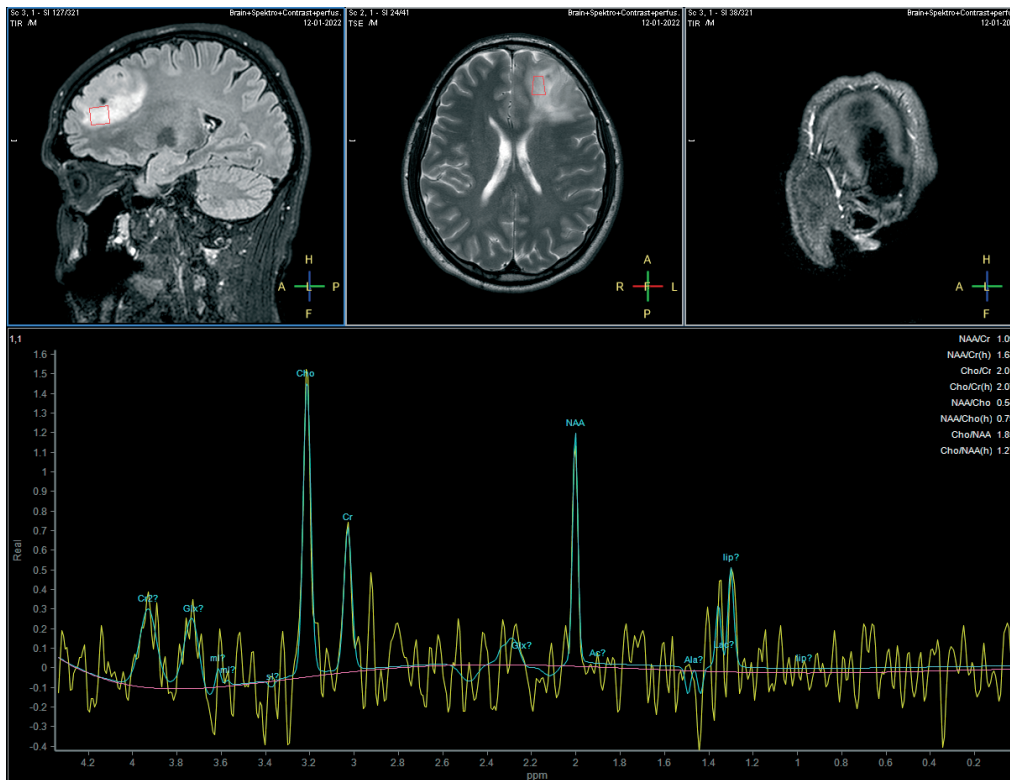


Figure 6. Magnetic resonance imaging image

Aliya Kadyrova, Kubat Ibraimov, G. Alin, Aidana Akbalaeva,
Cholpon Turatbek, Aziza Abdullaeva

Department of Radiology, I.K. Akhunbaev Kyrgyz State
Medical Academy, Bishkek, Kyrgyz Republic

Ethics: Informed consent was obtained from patients
before all procedures.

Peer-review: External

Conflict of interest: None to declare

Authorship: A.K., K.I., G.A., A.A., Ch.T., A.A. equally
contributed to preparation of article

Acknowledgement and funding: None to declare