

A patient with heart failure symptoms and continuous murmur

A 65-year-old man was admitted to hospital having dyspnea, fatigue, edema of both legs. Heart failure symptoms worsened during the last couple of weeks. He had long-standing arterial hypertension with poor control of arterial pressure without symptoms of coronary artery disease. Electrocardiogram showed sinus rhythm and left bundle branch block. Precordial auscultation revealed

a loud continuous murmur. Laboratory findings were unremarkable. Images (Fig. 1-4) were recorded during transthoracic echocardiography. Echocardiography showed left ventricular walls hypertrophy, normal systolic ventricular function, and moderate right ventricular dilatation.

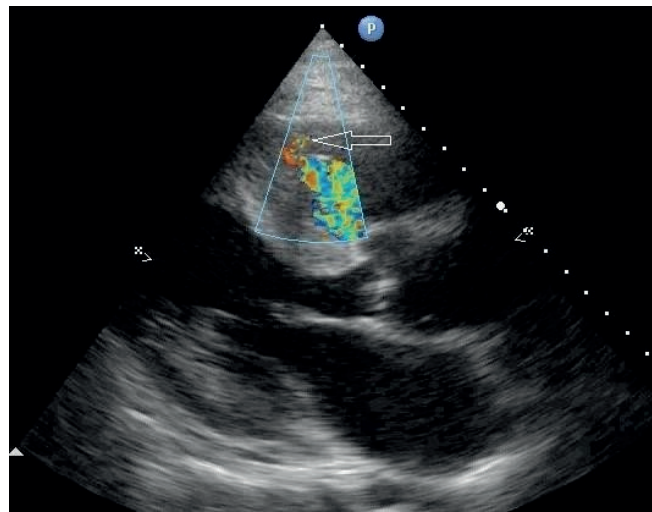


Figure 1. Echocardiography. Parasternal long-axis view. Colour Doppler echocardiography of turbulent flow in the right ventricle

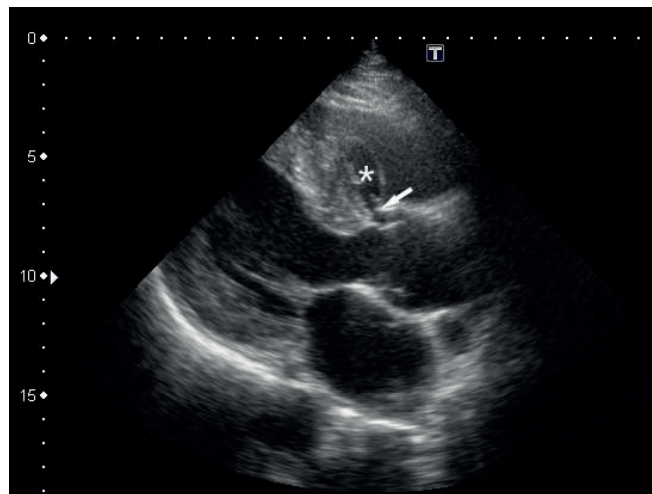


Figure 2. Echocardiography. Parasternal long-axis view. Echo-lucent cavity close to the right side of the interventricular septum

Address for Correspondence: Yuriy Ivaniv, Department of Diagnostic Radiology Danylo Halytsky National Medical University, Lviv, Ukraine

Email: yivaniv@gmail.com

Received: 31.07.2022 **Revised:** 18.08.2022 **Accepted:** 18.08.2022

Copyright ©2022 Heart, Vessels and Transplantation

doi: 10.24969/hvt.2022.333

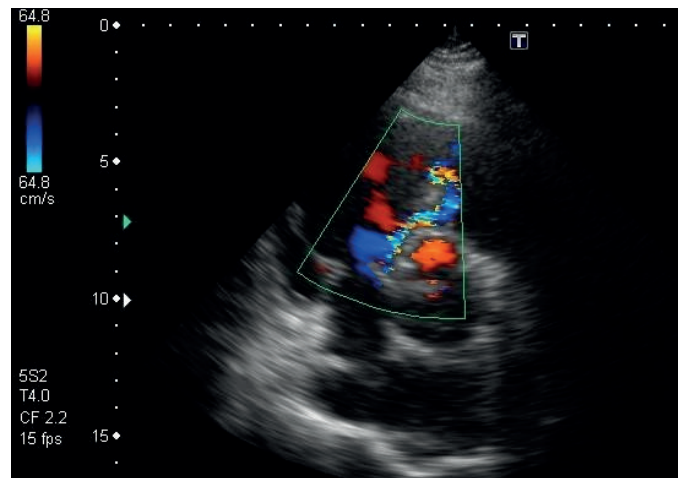


Figure 3. Echocardiography. Parasternal short-axis view. Color Doppler echocardiography of the turbulent flow

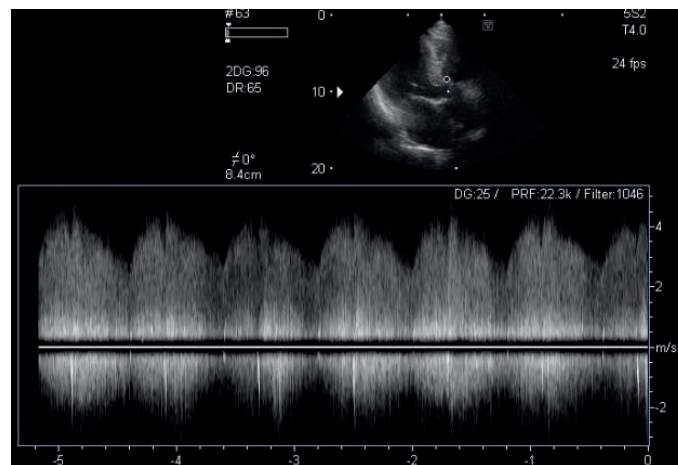


Figure 4. Continuous-wave Doppler of the turbulent flow in the right ventricle The differential diagnosis and which of the following is the correct answer:

1. Congenital ventricular septal defect with interventricular septum aneurysm
2. Postinfarction ventricular septal rupture
3. Ruptured sinus of Valsalva aneurysm,
4. Right coronary artery aneurysm
5. Coronary artery-right ventricular fistula

Nelya Oryshchyn, Yuriy Ivaniv Department of Diagnostic Radiology
Danylo Halytsky National Medical University, Lviv, Ukraine

Ethics: Informed consent was obtained from patient before procedures

Peer-review: Internal and external

Conflict of interest: None to declare

Authorship: N.O. and Y.I. equally contributed to case management and preparation of manuscript

Acknowledgement and Funding: None to declare