

Rare presentation of bicuspid aortic valve with severe stenosis complicated by mitral valve chordal rupture in peripartum period

Alay Parikh, Ishan Gohil, Utkarsh Sanghvi, Jignesh Kothari*

Department of Cardiovascular and Thoracic Surgery, U.N.Mehta Institute of Cardiology and Research Center. Civil Hospital Campus, Asarwa, Ahmedabad., Gujarat, India.

Abstract

Objective: Cardiac lesions in pregnancy has low incidence but when present can cause severe hemodynamic deterioration and major adverse cardiovascular events. Valvular lesions are relatively common in developing countries and these can mount to significant risk during pregnancy if not investigated and managed with a multi-disciplinary approach

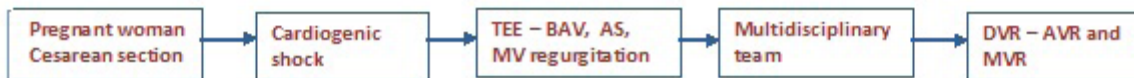
Case presentation: We report case of a pregnant patient who was diagnosed to have a cardiac lesion intra-operatively during cesarean section when the patient’s condition deteriorated on table. Patient was diagnosed to have bicuspid aortic valve with severe aortic stenosis and severe mitral regurgitation. Patient was taken for emergency surgery and operated for double valve replacement (DVR).

Conclusion: Early diagnosis of the condition during pregnancy and planned delivery can prevent such complications and ensure smooth course during the peripartum period to save life of the mother as well as the baby.

Graphical abstract

Rare presentation of bicuspid aortic valve with severe stenosis complicated by mitral valve chordal rupture in peripartum period

Cardiac lesions in pregnancy has low incidence but when present can cause severe hemodynamic deterioration and major adverse cardiovascular events. Valvular lesions are relatively common in developing countries and these can mount to significant risk during pregnancy if not investigated and managed with a multi-disciplinary approach. We report case of a pregnant patient who was diagnosed to have a cardiac lesion intra-operatively when the patient’s condition deteriorated on table. Patient was diagnosed to have bicuspid aortic valve with severe aortic stenosis with severe mitral regurgitation. Patient was taken for emergency surgery and operated for double valve replacement.



Key words: peripartum, chordal rupture, double valve replacement, bicuspid aortic valve

(Heart Vessels Transplant 2023; 7: 395-7 doi: 10.24969/hvt.2023.427)

Address for Correspondence*: Jignesh Kothari, Department of CVTS, U. N. Mehta Institute of Cardiology and Research Center, Civil Hospital Campus, Asarwa, Ahmedabad-380016, Gujarat, India.

Email: jvks20@yahoo.com **Mobile:** +91-9825845972, **Fax:** +91-079-22682092

Jignesh Kothari- ORCID: 0000-0002-7693-2037; Utkarsh Sanghavi-ORCID: 0000-0001-8757-7125

Received: 24.06.2023 **Revised:** 21.09.2023 **Accepted:** 22.09.2023

Copyright ©2023 Heart, Vessels and Transplantation

Introduction

Pregnancy is usually associated with very low mortality and good outcomes. However associated cardiac conditions remain leading cause of mortality during pregnancy (1). Pregnancy is associated with cardiac conditions in 1% of cases and major cardiac events occur in about 13% of these (2).

In the developing countries, occurrence of valvular heart disease during pregnancy is not uncommon. They present with cardiac complications such as cardiac failure, arrhythmias, thromboembolic episodes and even mortality during pregnancy (3%-5%) (3). Presence of bicuspid aortic valve with or without stenosis or regurgitation is most prevalent defect and is a common indication of cardiac surgery (2). Mitral valve chordal rupture is a very rare occurrence during pregnancy and peripartum period and has a very limited data on etiology and outcomes (4).

We hereby report a case of young patient with bicuspid aortic valve with severe stenosis complicated by mitral valve chordal rupture during the peripartum period.

Case report

A 28-year-old female patient, having uneventful antenatal period and no cardiac complaints underwent planned cesarean section at an outside hospital. During surgery, which was under spinal anesthesia, patient developed cardiogenic shock and inotropes were started. A physician was called in emergency who diagnosed severe ejection systolic murmur at aortic area and electrocardiogram showed left ventricular hypertrophy with strain pattern.

Hence, patient was referred to cardiology team in emergency. Patient was diagnosed on echocardiography to have bicuspid aortic valve with severe aortic stenosis with mean gradient of 104 mmHg along and severe mitral regurgitation. Patient was on kept on noninvasive positive pressure ventilation support.

After joint discussion by the Heart team comprising of cardiac surgeon, cardiologist and cardiac anesthetist, patient was taken for emergency surgery. On transesophageal echocardiography (TEE), patient had bicuspid aortic valve with severe aortic stenosis and anterior mitral leaflet was prolapse due to choral rupture of A2 segment.

Intra-operatively, the stenotic bicuspid aortic valve was excised; in view of multiple chordae rupture of anterior mitral leaflet, mitral valve was also decided to be replaced, hence excised with partial posterior mitral leaflet preservation. Aortic valve was replaced with 17 mm St. Jude Medical mechanical heart valve and mitral valve with 25 mm St. Jude Medical mechanical heart valve.

Post-operatively patient was kept on antiplatelet (aspirin 75mg once daily) and anticoagulant (warfarin), and INR (International Normalized Ratio) was maintained between 2.5 and 3.5. Post-operative recovery was smooth and uncomplicated.

At 12 months follow up, patient is asymptomatic and her INR is within therapeutic range.

Discussion

Acute cardiorespiratory distress in pregnancy can result from multiple causes such as pre-eclampsia, pulmonary embolism, amniotic fluid embolism, acute myocardial infarction, aortic dissection or peripartum cardiomyopathy.

During pregnancy there are many physiological changes occurring which can cause pulmonary edema. Case reports in medical literature on chordal rupture causing acute severe mitral regurgitation are scarce. There are a few causes proposed for chordal rupture such as mitral valve prolapse, infective endocarditis, rheumatic heart disease, connective tissue abnormality, ischemic heart disease or pregnancy induced chordal rupture. However, the underlying mechanism of spontaneous chordal rupture during pregnancy and peripartum period is still unclear (4).

Caves and Peneth et al. (5) reported the first case of chordal rupture in 19-year-old pregnant patient in 1968. Intra-operatively there was chordal rupture of posterior leaflet, which was replaced by frame mounted aortic homograft. The patient had homograft dehiscence from posterior annulus, which was re-sutured at the second operation (5).

In a report by Caves et al. (6), during the first operation, they noticed that the mitral annulus and leaflets were felt to be soft. Sex hormonal changes occurring during pregnancy might soften the annulus and leaflets by modulating the expression of matrix metalloproteinase and the deposition of matrix protein (4). During peripartum period, cardiac output increases up to 60-80% of that before onset of labor (7). These changes occurring during the pregnancy together with increased cardiac output is the proposed mechanism for chordal rupture in pregnancy. Pregnancy is a state of physiological volume overload, which indirectly adds to the severity of mitral regurgitation (4, 6).

Registry of Pregnancy and Cardiac disease (ROPAC) found that aortic valve disease is present in 23% pregnant patients with valvular heart disease. A patient with severe aortic stenosis, even if asymptomatic, is subjected to hemodynamic stress during peripartum period and may become symptomatic (1).

Use of spinal anesthesia in caesarean section may lead to major cardiovascular events. The most common cardiovascular response to spinal anesthesia is reduction in systemic vascular resistance and compensatory tachycardia and increase in stroke volume. This sudden reduction of systemic vascular resistance increases the gradient in case of aortic stenosis and further worsens the condition (7).

This explains in our patient who previously was asymptomatic, and developed acute cardiopulmonary distress intraoperatively under the effect of spinal anesthesia, which was complicated by chordal rupture in the peripartum period. This combined lesion of severe aortic stenosis due

to thickening of bicuspid aortic valve and severe mitral regurgitation due to chordal rupture along with volume overloaded heart in a pregnant female leads to critically low cardiac output and increased back pressure changes, leading to increased pulmonary venous pressure and flooding of lungs leading to hemodynamic collapse.

Such a situation can be avoided by proper antenatal work up comprising of electrocardiogram and echocardiography during pregnancy. On suspicion of a cardiac disease, it is preferable to plan delivery at a tertiary care center having cardiology team in backup.

Conclusion

Cardiac condition during pregnancy is rare but if present, can complicate the pregnancy and peripartum period if not managed properly. For this an early detection and proper planning of complete course of pregnancy is inevitable. Basic investigation such as electrocardiogram and echocardiography if undertaken routinely during antenatal work up can help us save not one but two lives.

Ethics: Informed consent was obtained from patient before procedures.

Peer-review: External and internal

Conflicts of interest: None to declare

Authorship: A.P., I.G., U. S., and J.K. equally contributed to case management and manuscript preparation

Acknowledgement and funding: None to declare

References

1. Orwat S, Diller GP, van Hagen IM, Schmidt R, Tobler D, Greutmann M, et al. Risk of pregnancy in moderate and severe aortic stenosis. *J Am Coll Cardiol* 2016; 68: 1727–37.
2. Driul L, Meroi F, Sala A, Delrio S, Pavoni D, Barbariol F, et al. Vaginal delivery in a patient with severe aortic stenosis under epidural analgesia, a case report. *Cardiovasc Ultrasound*. 2020; 18: 43.
3. Deedwania P, Dadhwal V, Sharma KA. Advanced pregnancies with valvular heart disease requiring peripartum cardiac intervention: two case reports and literature review. *Cureus* [Internet]. 2022 [cited 2022 Dec 24]; Available from: <https://www.cureus.com/articles/40819-advanced-pregnancies-with-valvular-heart-disease-requiring-peripartum-cardiac-intervention-two-case-reports-and-literature-review>
4. Chiu FH, Yang CJ, Huang CK, Lin CY, Tsai SH. Spontaneous chordae tendineae rupture during peripartum. *Am J Emerg Med* 2018; 36: 1127.e1-1127.e3.
5. Caves PK, Paneth M. Acute mitral regurgitation in pregnancy due to ruptured chordae tendineae. *Br Heart J* 1972; 34: 541–4.
6. Ohishi S, Nitta H, Chinen Y, Kinjo T, Masamoto H, Sakumoto K, et al. Acute congestive heart failure due to ruptured mitral chordae tendineae in late pregnancy. *J Obstet Gynaecol Res* 2013; 39: 724–6.
7. Sanghavi M, Rutherford JD. Cardiovascular physiology of pregnancy. *Circulation* 2014; 130: 1003–8.