

Changing the diagnostic paradigm of the ECG diagnosis of left ventricular hypertrophy

In the previous editorial (1) a question of the “hot topic” research was discussed and illustrated using the example of the electrocardiographic (ECG) diagnosis of left ventricular hypertrophy (LVH). In this editorial, I want to share with you the progress in understanding of this topic by the international electrocardiographic societies and present the new diagnostic paradigm (2).

The diagnosis of left ventricular hypertrophy has been apparently solved by introducing and further development of the powerful imaging methods. Echocardiography and cardiac magnetic resonance can provide details on the anatomy, structure, as well as on the number of functional characteristics of hypertrophied left ventricle. The diagnostic performance of ECG in estimating the LV mass cannot compete with these methods. However, this problem is not as straightforward as it might appear.

The discrepancies between the ECG criteria for LVH (ECG-LVH) are chronically documented, showing low sensitivity, but also questionable specificity (3). Since the diagnostic performance of ECG-LVH criteria are evaluated according to their ability to estimate the increased left ventricular mass, these discrepancies are considered as the weakness of ECG.

However, ECG by principle cannot estimate the mass, it records the electrical phenomena of the heart on the body surface. This makes it a very unique diagnostic method, and it is the strength of ECG. The joint paper of the International Society of Electrocardiology and the International Society for Holter Monitoring and Noninvasive Electrocardiology (2) stresses this aspect for reasoning for the need of changing the diagnostic paradigm of ECG-LVH.

Left ventricular hypertrophy is not a simple increase in left ventricular mass, but it is a complex rebuilding of the left ventricle at organ, tissue cellular, subcellular and molecular levels.

Naturally, the interplay of these numerous factors affects the electrical impulse propagation in left ventricular myocardium and consequently the morphology of the QRs complex (Fig. 1).

The anatomical changes are observed in the shape of the left ventricle, its wall thickness and dimension of the LV cavity. The structural changes include the increase of the size of cardiomyocytes, their spatial arrangement, the amount and distribution of gap junctions, and considerable changes of interstitium, such as fibrosis, inflammation, ischemic areas, adipose tissue, etc. In the cardiomyocytes, the action potential amplitude and duration are altered, as well as intracellular and extracellular conductivity, resulting in local or diffuse changes in conduction velocity. Due to the changes in the interstitium the proportion of the excitable tissue – i.e. the electrically active tissue with respect to the electrically inactive tissue is changed. This leads to a whole spectrum of QRS patterns observed in LVH: increased QRS complex amplitude, QRS complex duration prolongation, left axis deviation, left anterior fascicular block, incomplete and complete left bundle branch block, pathological Q wave, fragmented QRS complex, but as well QRS complex within normal limits.

Since the focus in ECG-LVH diagnosis has been mainly on the increased QRS amplitude, there are gaps in our knowledge. On one hand, there is a need to consider the whole spectrum of the QRS patterns in LVH, on the other hand to reduce the gap between the clinical interpretation of ECG in LVH and basic science and pathophysiological knowledge. Understanding this knowledge is vital in relation to the clinical decision making regarding diagnosis and prognosis, as well as selecting targeted therapy and its monitoring.

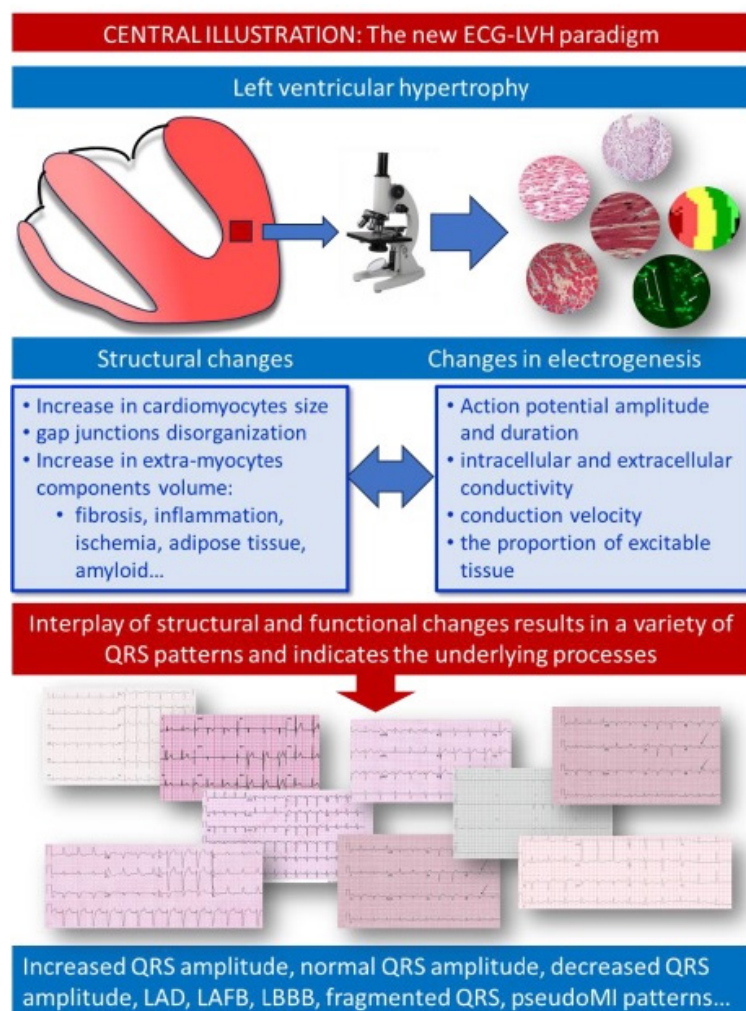


Figure 1. The new ECG-LVH paradigm

(Republished from reference 2 with permission of Elsevier, Copyright©2023)
ECG – electrocardiogram, LVH – left ventricular hypertrophy

Summarizing, the ECG / QRS patterns associated with LVH are markers of altered electrical properties of hypertrophied myocardium we need to understand better. The new paradigm of ECG diagnostic of LVH opens thus an exciting area for clinical and basic research.

Ljuba Bacharova

International Laser Center CVTI, Bratislava, Slovak Republic

Peer-review: Internal

Conflict of interest: None to declare

Authorship: L.B.

Acknowledgment and funding: None to declare

References

1. Bacharova L. What research topic is the “hot” research topic? Heart Vessels Transplant 2018; 2: 2. Doi: 10.24969/hvt.2017.37
2. Bacharova L, Chevalier P, Gorenec B, Jons C, L, YG, Locati ET, et al. ISE/ISHNE expert consensus statement on ECG diagnosis of left ventricular hypertrophy: The change of the paradigm. The joint paper of the International Society of Electrocardiology and the International Society for Holter Monitoring and Noninvasive Electrocardiology. J Electrocardiol 2023; 81: 85–93. Doi: 10.1016/j.jelectrocard.2023.08.005
3. Pewsner, D, Jüni P, Egger M, Battaglia, M, Sundström J, Bachmann LM. Accuracy of electrocardiography in diagnosis of left ventricular hypertrophy in arterial hypertension: systematic review. BMJ 2007; 335: 711–14. Doi: 10.1136/BMJ.39276.636354.AE