

# A safe single-stage strategy for surgical repair of redo coarctation of aorta with coronary artery bypass grafting in adults: A case report

Thakut Gowtham, Utkarsh Sanghavi, Ishan Gohil, Devvrat Desai, Jignesh Kothari\*

Department of Cardiovascular & Thoracic Surgery, U. N. Mehta Institute of Cardiology and Research Center, Civil Hospital Campus, Asarwa, Ahmedabad, Gujarat, India

## Abstract

**Objective:** The association of coarctation of aorta (CoA) and coronary artery disease is rare. To formulate single stage safe strategy for redo repair of aortic coarctation and simultaneous coronary artery bypass grafting (CABG).

**Case presentation:** The present case report describes a 55-year-old male, who underwent a redo safe single -stage surgical repair for both pathologies. CoA was tackled by ventral aortic repair followed by coronary artery bypass grafting under cardiopulmonary bypass. The vascular prosthesis was anastomosed to descending thoracic aorta in end-to- side fashion, and it was located posterior to the inferior vena cava through the oblique sinus but inferior to the superior vena cava and curved around the right atrium, anastomosed to ascending aorta.

**Conclusion:** Ventral aortic repair through a midline approach is our preferred technique for redo surgical repair of CoA. Dual arterial cannulation ensures adequate perfusion of both upper and lower extremities.

**Key words:** coarctation of aorta, coronary artery bypass surgery, single stage surgery, surgery operative procedures

(Heart Vessels Transplant 2024; 8: 119-3. doi: 10.24969/hvt.2023.431)

## Introduction

Coarctation of the aorta (CoA) occurs in approximately 4 of 10,000 live births and comprises 5% to 8% of congenital heart disease (1). Because of its long-term tolerance, CoA in adults is associated with a high level of collateral circulation and vascular variation. The association of aortic coarctation with coronary artery disease is not rare in patients past 35 years of age (2). Few patients with aortic coarctation become symptomatic at 30–40 years of age when the occurrence of coronary artery disease increases. Surgical management becomes difficult particularly when both the pathologies coexist. Usually a median sternotomy and repair of coarctation using a long vascular prosthesis, which is connected to the descending thoracic or abdominal aorta or iliac artery is preferred (3-5).

In this report, we describe our experience of redo repair of aortic coarctation and simultaneous coronary artery bypass grafting (CABG) using single-stage surgical technique with good outcomes.

## Case report

A 55-year-old male presented to our hospital with headache, chest tightness, dyspnea, palpitations on exertion. He had been categorized as NYHA class IV since 4 to 5 months and had history of claudication pain in both lower limbs. He had a prior history of CoA repair using a graft between left subclavian artery to descending thoracic aorta in 2008 via left posterolateral thoracotomy.

Echocardiography showed normal left ventricular ejection fraction (LVEF) with mild aortic, and mitral valve regurgitation and concentric left ventricular hypertrophy (LVH). Computed tomography angiography (CTA) and 3D CT scan reconstruction revealed post ductal CoA with multiple enlarged collaterals in mediastinum, paravertebral region, bilateral internal mammary arteries and absence of contrast filling within the graft suggesting graft occlusion between left subclavian artery and descending thoracic aorta (Fig. 1). Coronary angiography revealed >90% stenosis in the left anterior descending (LAD) artery and proximal right coronary artery - 90%. After discussing with interventional cardiologist and radiologist, decision was taken to perform redo surgery.

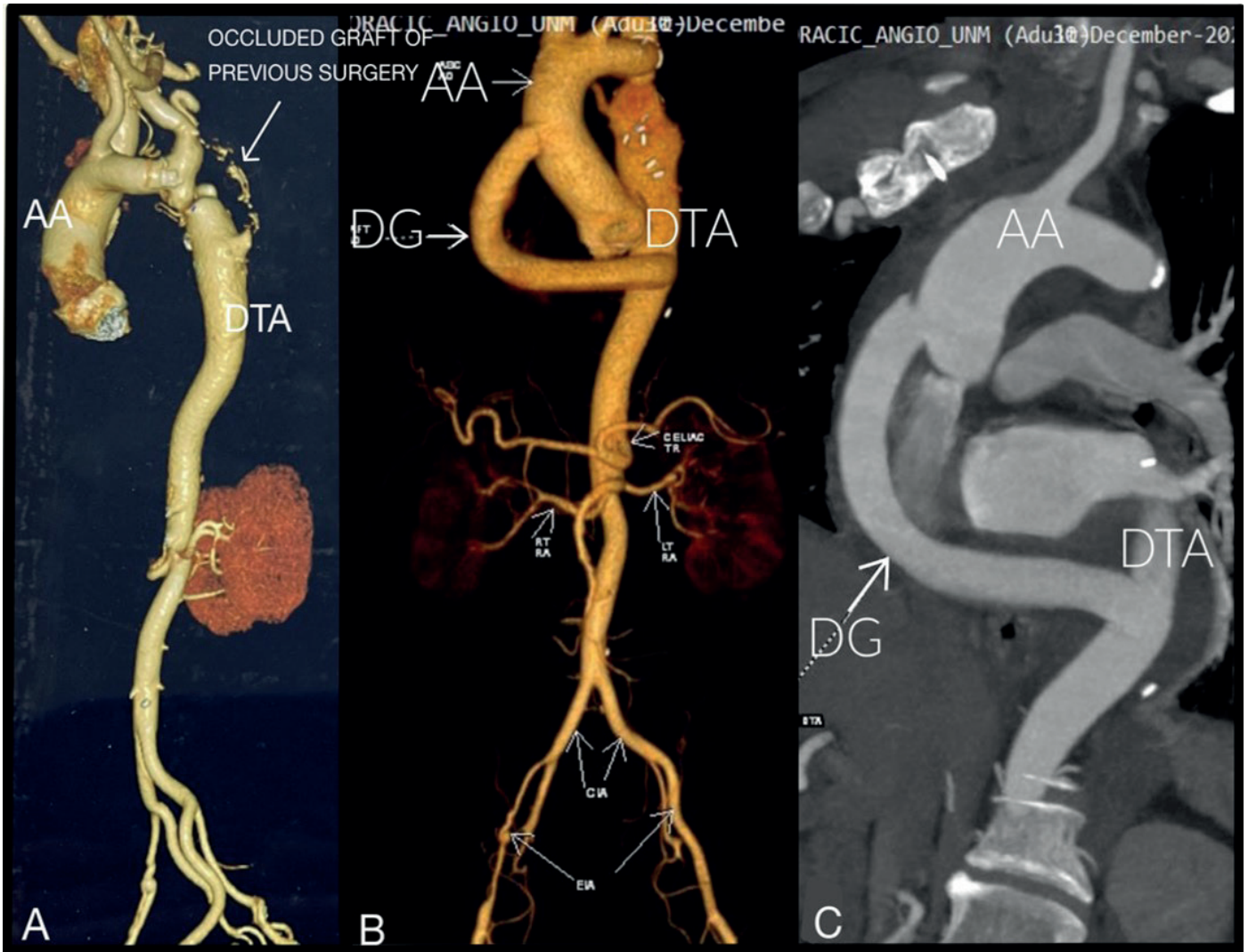
**Address for Correspondence:** Jignesh Kothari, Department of Cardio Vascular and Thoracic Surgery U. N. Mehta Institute of Cardiology and Research Center, Civil Hospital Campus, Asarwa, Ahmedabad, Gujarat, 380016, India

**Email:** jvks20@yahoo.com **Phone:** +93 9825845972, **Fax:** +93-079-22682092

Jignesh Kothari: ORCID 0000-0002-7693-2037, Thakut Gowtham: ORCID 0000-0002-1284-8872, Utkarsh Sanghavi: ORCID 0000-0001-8757-7125, Ishan Gohil: ORCID 0000-0002-0573-1211, Devvrat Desai: ORCID 0000-0001-7083-9985

**Received:** 18.09.2023 **Revised:** 13.10.2023 **Accepted:** 14.10.2023

**Copyright ©2023 Heart, Vessels and Transplantation**



**Figure 1. A) Preoperative CTA showing CoA, with occluded graft between left subclavian artery and descending thoracic aorta; B) and C) Postoperative CTA showing patent Dacron graft from ascending aorta to descending thoracic aorta**


AA- ascending aorta, CoA- coarctation of aorta, CTA – computed tomography angiography, DG- Dacron graft, DTA- descending thoracic aorta

### Operative technique

After written, informed consent was obtained from patient, we performed ascending-to-descending aortic bypass, CoA repair, and CABG. Right radial and left femoral arterial lines were secured. The surgical approach involved a median sternotomy. Cardiopulmonary bypass was established between the right common femoral artery, the right axillary artery done by end-to-side anastomosis of 6mm polytetrafluoroethylene (PTFE) graft to maintain perfusion to both upper and lower half of the body, and the superior and inferior vena cava (Fig. 2). Left interior mammary artery (LIMA) was harvested. Antegrade root cold cardioplegia was given. Following the diastolic arrest of heart, the apex was elevated out of the pericardial wall to expose the posterior pericardium. A longitudinal posterior pericardial incision

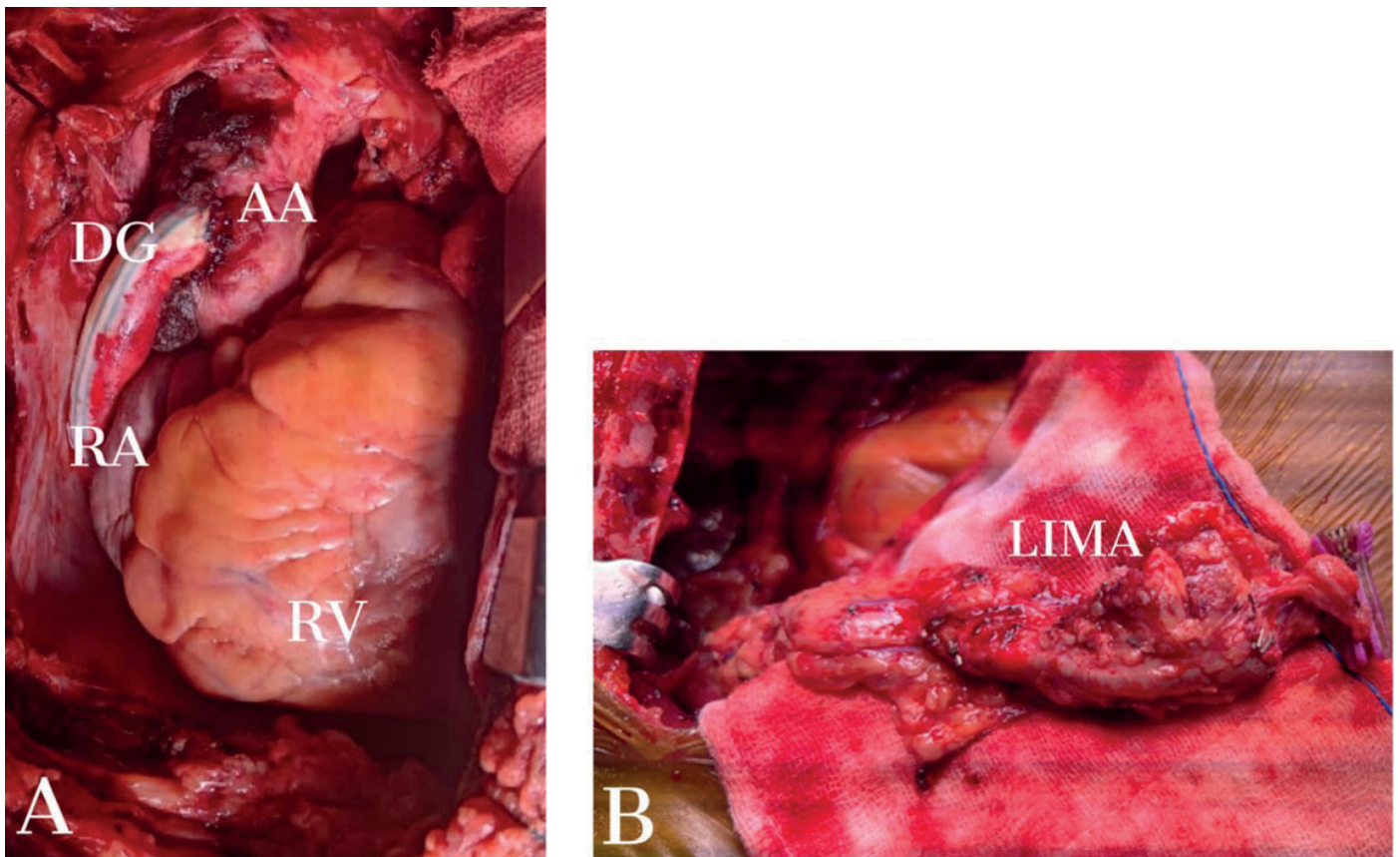
over the descending aorta was made, which allowed for exposure of the anastomotic stoma. A sidewall vascular clamp was used to control the descending aorta, and end-to-side anastomosis of a 16 mm Dacron graft to the descending aorta was deployed by a continuous 5-0 polypropylene suture. The graft was passed posterior to the inferior vena cava, anterior to right inferior pulmonary vein through the oblique sinus but inferior to the superior vena cava and curved around the right atrium (Fig. 3A). During graft suturing, moderate hypothermic circulatory arrest (28°C) was achieved. The proximal anastomosis of the graft to aorta was done using 5-0 Prolene using sidewall vascular clamp. CABG was performed with the LIMA to LAD. The operation time was 220 min, the cardiopulmonary bypass time was 110 min, and the cross-clamp time was 60 min.





**Figure 2. A) Intraoperative picture illustrating right femoral arterial cannulation using PTFE graft B) intraoperative picture illustrating right axillary arterial cannulation using PTFE graft**

PTFE – polytetrafluoroethylene



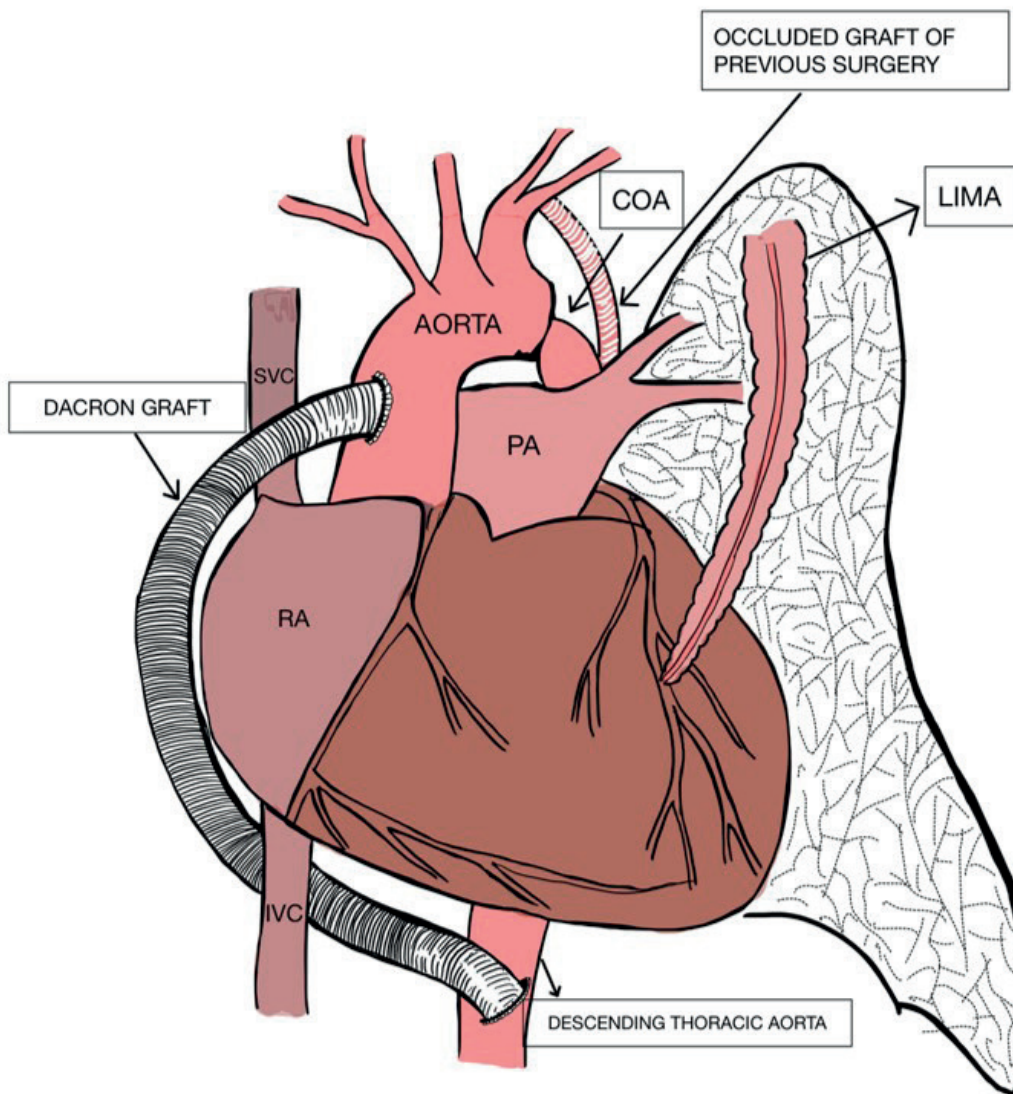
**Figure 3. A) Intraoperative picture showing anastomosis of Dacron graft between ascending aorta and descending thoracic aorta B) Intraoperative picture of hypertrophied LIMA**

AA – ascending aorta, DG – Dacron graft, LIMA - left internal mammary artery, RA- right atrium, RV – right ventricle

The right coronary artery was not re-vascularized as it was very small in caliber (<1mm).

The patient had 3 days of intensive care unit stay, and was discharged on day 8. Post-operative 3D CT scan

reconstruction revealed good flow from ascending to descending aorta with no leak and flowing LIMA to LAD (Fig. 4). At 6-months follow-up, patient was in NYHA class II with stable hemodynamics.



**Figure 4. Diagrammatic representation of ventral aortic repair for CoA and LIMA to LAD grafting**

CoA- coarctation of aorta, LAD – left anterior descending artery, LIMA- left internal mammary artery

### Discussion

The simultaneous correction of ischemic heart disease and CoA requires two different stages of operation. Correction of the coarctation alone is associated with increased perioperative myocardial infarction (6). On the other hand, correction of the cardiac lesion alone is associated with increased postoperative renal failure and paraplegia as a result of inadequate distal organ perfusion (7). The association of CoA with coronary artery disease is common in

patients after 4th decade of life due to bimodal presentation (2). Patients with severe CoA are either treated in infancy and/or childhood or die during childhood without treatment. The majority of CoA patients who survive to adulthood develop compensatory collateral circulation. Surgical difficulties are likely for elderly patients with CoA and other cardiovascular diseases due these collaterals.



Cannulation technique which we had used in our case is preferred, so as to secure sufficient cerebral protection and to maintain perfusion to lower extremity (Fig. 2). It is difficult to direct the graft around the right margin of the heart without compressing the right atrium or right ventricle. This is very well done by directing the graft behind the inferior vena cava and anterior to the right inferior pulmonary vein but inferior to superior vena cava in the oblique sinus. This course also ensures that the graft remains in a posterior location and to the right side of the sternum, which can reduce the complications of redo sternotomy less.

We used the hypertrophied internal mammary artery for coronary grafting because the difference in luminal diameters did not preclude the procedure. We have not found any reference concerning the use of the hypertrophied internal mammary artery as a coronary graft. Internal mammary artery dissection, identification of its intercostal branches and the placement of ligatures or clips offers no difficulties. This was a macroscopically healthy artery, with 3 mm caliber, and no atheromatous plaques nor clarification with good flow.

### Conclusion

Ventral aortic repair through a midline approach is our preferred technique for redo surgical repair of this entity, because it avoids the extensive network of collateral vessels on the chest wall, enables simultaneous treatment of associated lesions as in our case with CABG, and in all likelihood reduces morbidity and mortality. Dual arterial cannulation ensures perfusion of both extremities. It also avoids or minimizes the risk of paraplegia, and avoids the need for an additional surgical sternotomy or thoracotomy with a staged procedure.

Ethics: Informed consent was obtained from patient before all procedures. The patient consented to the submission and publication of this report.

As per our Institute protocol, we do not have to approve the image and case report before publication.

**Peer-review:** External and internal

**Conflict of interest:** None to declare

**Authorship:** T.G., U.S., I.G., D.D., and J.K. equally contributed to case management and preparation of manuscript

**Acknowledgment and funding:** None to declare

### References

1. Hoffman JI, Kaplan S. The incidence of congenital heart disease. *J Am Coll Cardiol* 2002; 39: 1890–900.
2. Cohen M, Fuster V, Steele PM, Driscoll D, McGoon DC. Coarctation of the aorta. Long-term follow-up and prediction of outcome after surgical correction. *Circulation* 1989; 80: 840–5.
3. Fernandez de Caleyra D, Duarte J, Eguren A, Torrente N, Lozarro A, Nuche J. Combined therapy of coarctation and coronary artery disease in an adult. *Thorac Cardiovasc Surg* 1993; 41: 127–9.
4. Bartoccioni S, Giombolini C, Fiaschini P, Martinelli G, Fedeli C, Di Lazzaro D, et al. Aortic coarctation, aortic valvular stenosis, and coronary artery disease: combined one-stage surgical therapy operation. *J Card Surg* 1995; 10: 594–6.
5. Thomka I, Szedo F, Arvay A. Repair of coarctation of the aorta in adults with simultaneous aortic valve replacement and coronary artery bypass grafting. *Thorac Cardiovasc Surg* 1997; 45: 93–6.
6. Pethig K, Wahlers T, Tager S, Borst FG: Perioperative complications in combined aortic valve replacement and extraanatomic ascending-descending bypass. *Ann Thorac Surg* 1996, 61: 1724-6.
7. Brewer LA, Fosburg RG, Mulder GA, Verska JJ. Spinal cord complications following surgery for coarctation of the aorta: a study of 66 cases. *J Thorac Cardiovasc Surg* 1972, 64: 368-81.