

Case report

Simultaneous surgery in combination of double myxoma of the right atrium and coronary heart disease

Khamidulla A. Abdumajidov^{1,2}, A.A. Mansurov¹, Sh. T. Urakov¹

Republican Scientific and Practical Medical Center of Surgery named after academician V. Vakhidov, Tashkent, Uzbekistan

Bukhara State Medical Institute named after Abu Ali ibn Sino, Bukhara, Uzbekistan

Objective: Cardiac tumors are rare pathology, and myxoma is the most frequently encountered. Co-existence of double myxoma or right heart and coronary artery disease is a rare condition.

The aim of our case report is to demonstrate a case with successful simultaneous surgical removal of myxoma and CABG in a patient with double myxoma of right heart and severe multivessel coronary artery disease, concomitant type 2 diabetes and heart failure.

Case presentation: A 68-year-old patient was admitted with typical complaints of severe shortness of breath, palpitations, lack of air, pain in the heart, weakness. From the anamnesis, it was revealed that the above complaints appeared over the past 4 years, he had also diabetes. Patients had NYHA functional class III-IV. Echocardiography revealed a large mobile mass in the cavity of the right atrium and right ventricle, periodically obturating the right atrioventricular orifice. Coronary angiography displayed multivessel coronary artery disease.

We performed the simultaneous operation of double myxoma removal and coronary bypass surgery – arterial graft – left internal mammary artery to left anterior descending artery and venous graft from aorta to posterior descending artery under cardiopulmonary bypass. The surgery was successful and without complication. The patient was transferred from intensive care unit to ward on the 4th day after surgery and was discharged on the 10th day.

Conclusion: Our case confirms the possibility of successful surgical treatment of several severe pathologies of the cardiovascular system as double myxoma removal and coronary bypass surgery, with the right choice of surgical tactics and well-coordinated work of a team of cardiac surgeons, cardiac anesthesiologists, perfusionists, cardiologists, and reanimatologists.

Key words: cardiac tumor, cardiac surgery procedures, coronary artery disease, myxoma, coronary bypass surgery, myxoma removal

(Heart Vessels Transplant 2024; 8: doi: 10.24969/hvt.2023.433)

Introduction

One of the rare diseases of the cardiovascular system are neoplasms of the heart (1-10). According to statistics, the latter constitute 0.0017-0.02% of the structure of cardiovascular pathologies. Among all types of heart tumors, the most common are myxomas, which, although morphologically are benign, are considered malignant in course and possible complications (1-3).

In the history of the development of onco-cardiac surgery, before the development of highly informative ultrasound examinations, the diagnosis of neoplasms of

the heart was difficult, most cases in practice were autopsy findings (7,9). With the introduction of highly informative non-invasive methods of ultrasound diagnostics, the detection of tumors has improved significantly. Currently, the routine methods for diagnosing myxoma are echocardiography with Doppler echocardiography and computed tomography (3, 5, 6, 8). Therefore, at present, various variants of combined pathologies of the heart and blood vessels are being increasingly identified, which includes our case - a double myxoma of the right atrium co-existent with coronary heart disease.

Address for Correspondence: Khamidulla A. Abdumajidov, SaibHodjaev Str. 49, Shaihantohurskiy region, Tashkent, Uzbekistan

E-mail: Hamidulla06@mail.ru **Mobile:** + 99897 777-07-70 **ORCID:** 0000-0001-5077-7174.

Received: 19.04.2023 **Revised:** 07.08.2023 **Accepted:** 08.08.2023

Copyright ©2023 Heart, Vessels and Transplantation

Given the rarity of the combination of myxoma and coronary artery disease, and the unresolved issues of simultaneous surgical correction of this pathology, we decided to share with our experience in the treatment of myxoma of the heart, complicated by coronary heart disease, requiring simultaneous surgery of myxoma removal and coronary bypass surgery (CABG) under cardiopulmonary bypass (CPB) and cardioplegia (CP).

The aim of our case report is to demonstrate a case with successful simultaneous surgical removal of myxoma and CABG in a patient with double myxoma of right heart and severe multivessel coronary artery disease, concomitant type 2 diabetes and heart failure.

Case report

A 68-year-old patient was admitted to the Department of Cardiac Surgery of the RSPMCH named after .acad. V. Vakhidov on 10.06.2019 with typical complaints of

severe shortness of breath, palpitations, and chest pain, weakness. From the anamnesis, it was revealed that the above complaints had appeared 4 years ago, gradually increased: if at the beginning of the disease shortness of breath was insignificant, then in recent months, it had increased. The pain in the region of the heart also increased. According to the patient, he suffers from diabetes mellitus, was periodically treated in a hospital, but without much effect.

On May 29, 2019, he applied to our consultative clinic, where echocardiography (Fig. 1) revealed a large mass (structural formation) in the cavity of the right atrium (RA) and right ventricle (RV), the latter was mobile, the base and structure of the tricuspid valve was difficult to determine. The size of the formation was 110x46-45mm, it was close to the tricuspid valve, periodically obturating the right atrioventricular orifice.

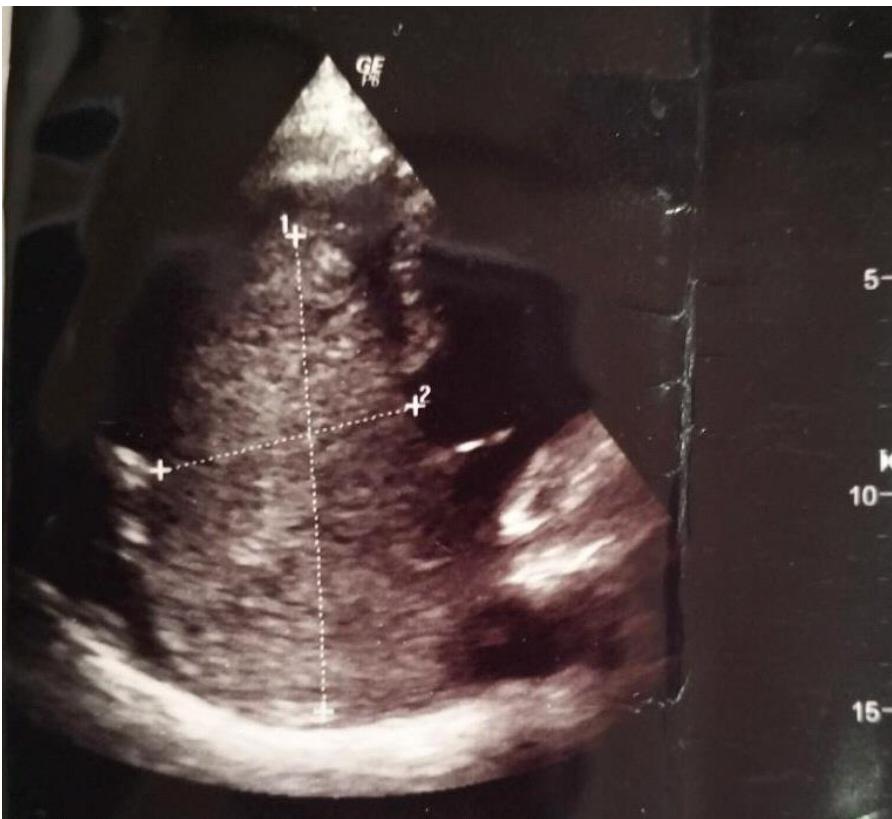

Figure 1. Echocardiography image showing h a large myxoma of the right atrium and right ventricle with obturation of tricuspid valve

The diagnosis was confirmed by multislice computed tomography revealing a structural formation in the cavity of the right atrium, right ventricle, 95x40x46 mm in size, obturating the tricuspid foramen. In addition, computed tomography identified grade 1 aortic valve calcification, multiple coronary artery stenoses, and moderate hydropericarditis.

Coronary angiography (Fig. 2) revealed multiple stenoses of the left (LCA) and right (RCA) coronary arteries: RCA - up to 90-95%, the posterior descending artery (PDA) - up to 85%, the posterolateral branch (PLB) - up to 70%; LCA - left anterior descending artery (LAD) - up to 85%, left circumflex artery (LCX) - up to 70%, obtuse marginal branch (OM) - up to 80%, and diagonal branch - up to 70%.

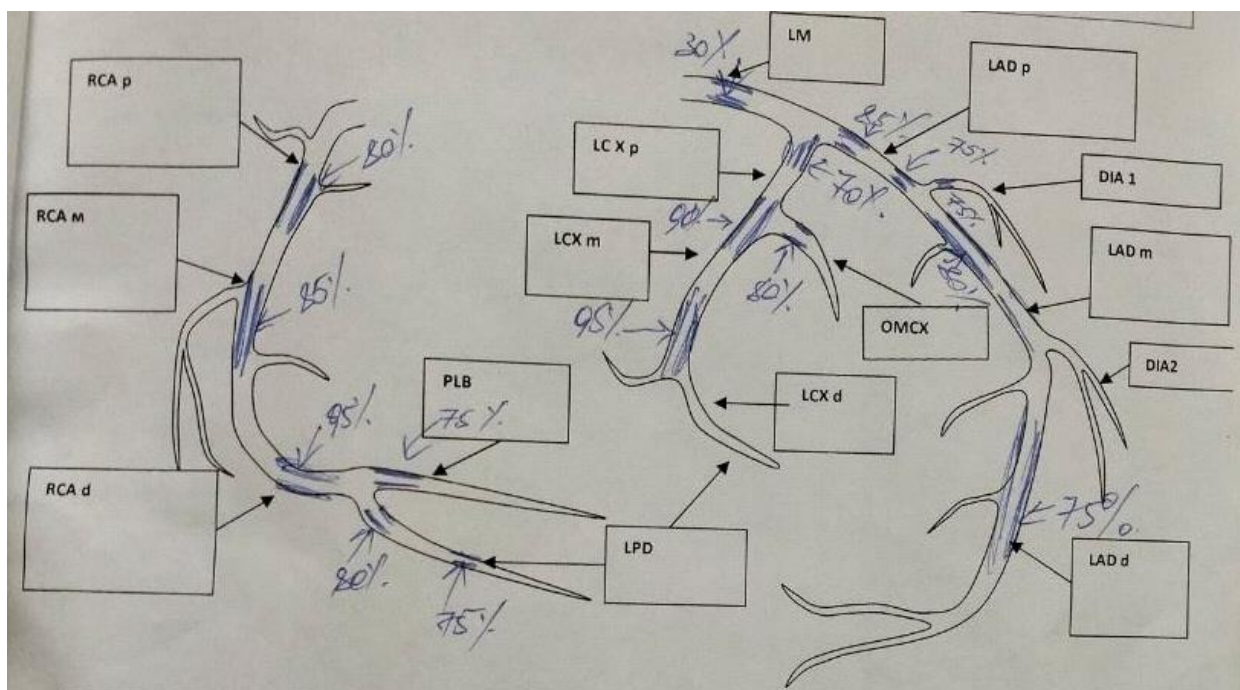


Figure 2. Coronary angiography datasheet: multiple critical coronary artery stenoses

DIA- diagonal branch, d-distal, LAD - left anterior anterior descending artery, LCX - left circumflex artery, LM- left main coronary artery, m-mid, OM - obtuse marginal branch, PDA - posterior descending artery, PLB - posterolateral branch, p - proximal, RCA - right coronary artery

After the consultation with cardiologists, cardiac surgeons, perfusionists, anesthesiologists and reanimatologists, it was decided to operate the patient simultaneously: it was planned to remove the RA and RV myxoma and perform CABG with the imposition of mammary coronary and aortocoronary bypass surgery in hemodynamically significant vessels under CPB and CP conditions.

After appropriate preparation, on 06.18.2019, simultaneous operation was performed: removal of a double myxoma of the RV with mammary coronary bypass and aortocoronary bypass grafting under CPB and CP. A median sternotomy was performed. Longitudinal pericardiotomy. Isolation of the left internal mammary artery (LIMA) for the mammary

bypass. The revision established an intraoperative diagnosis: a large double myxoma of the RA with dimensions of 11.5x8mm and 7x5 mm attached to the dome of the RA, located close to the mouth of the superior vena cava, with dimensions of 4x3 mm. Critical stenoses of the LAD, RCA, PDA, and LCX.

The plan of the operation: the first stage was the removal of the RA and RV myxoma with sanitation and restoration of the atrial septum, the atrioventricular orifice; subsequently on the 2nd stage, taking into account the suitability for grafting and hemodynamic significance, it was decided to perform only double grafting: arterial - LIMA to the LAD and venous - aorta to the PDA under conditions of CPB and CP.

After cannulation of the ascending aorta and vena cava, cardioplegia into the aortic root (antegrade), CPB was started, followed by clamping on the aorta and CP. Asystole was induced.

Myxoma removal (Fig. 3) - we opened longitudinally wide RA. Revision: the presence of a double myxoma of the RA, measuring 11x7 and 7x5 mm, the base is about 3.5 mm, the tumor originated from the fossa ovalis of the interatrial septum, was dark red in color, jelly-like in consistency, with seals in the center and along the edges of the tumor. The tumor of the dome of the RA was small in size 3x3.5 mm, the structure was identical.

Tumors were removed without fragmentation with excision of the base, together with the structures of the interatrial septum. The base was treated with betadine, washed repeatedly with saline. Interatrial septum was restored by two-row suturing (Prolene 4\0) - hermetically. During the revision, relative regurgitation (up to 2 degrees) of the tricuspid valve was noted, moderate dilatation of the fibrous ring was noted, but the valve was assessed as competent. Washing the cavity of the RA. No other pathologies were identified. Suturing the wall of the RA with a two-row suture.

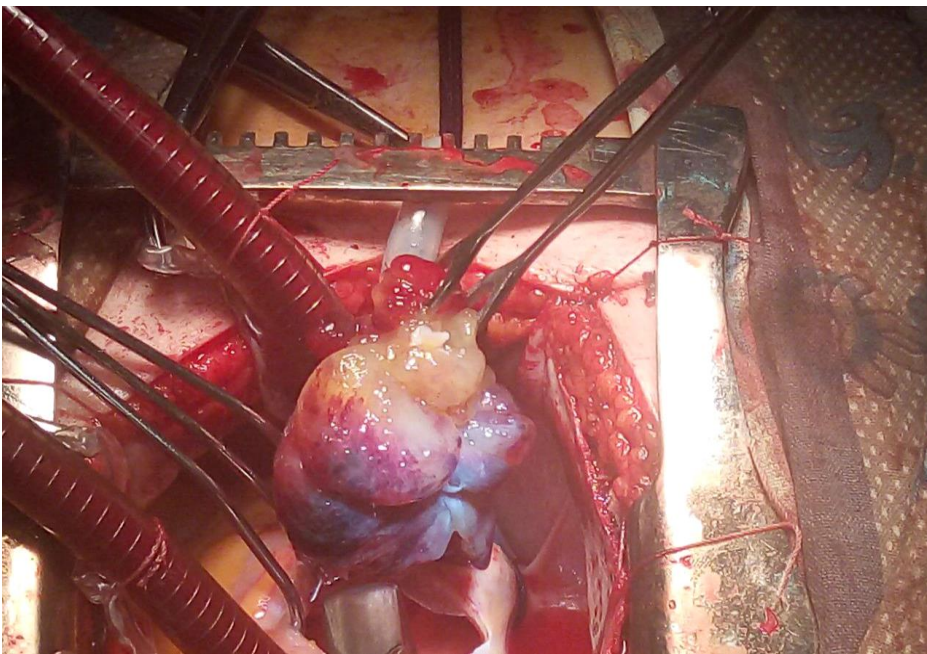


Figure 3. Intraoperative view of the 1st stage of correction: removal with of right atrial and right ventricular myxoma

CABG (Fig. 4 and Fig.5) - the revision revealed critical stenoses of the RCA up to 95%, LCA - LAD - 85%, PDA - 85%. LAD with a diameter of about 2 mm, a distal shunt was placed between the LIMA artery and the LAD. The tightness was checked. An aorto-coronary bypass was also placed between the PDA and the aorta. The shunt was sealed. Hemostasis. Further stages of the operation continued according to the standard program. Aorta cross-clamp time - 93 min, CPB - 142 min, temperature - 32.4 C°. Warming up to 37C°. Prevention of air embolism. Removal of the clamp from the aorta. Cardiac activity was restored independently.

Subsequent medical correction with stabilization of hemodynamics. CPB was stopped. General hemostasis. Gradual decannulation of the vena cava, CP cannula and aorta with hemostasis of all areas of intervention. Myocardial electrode was placed in the RV. Approximation of the edges of the sternum with a stylus. Layer-by-layer suturing of the wound of the sternum, aseptic bandage. Subsequently, we stabilized hemodynamic parameters, blood gases and other parameters, tests and transferred patient to the intensive care unit.

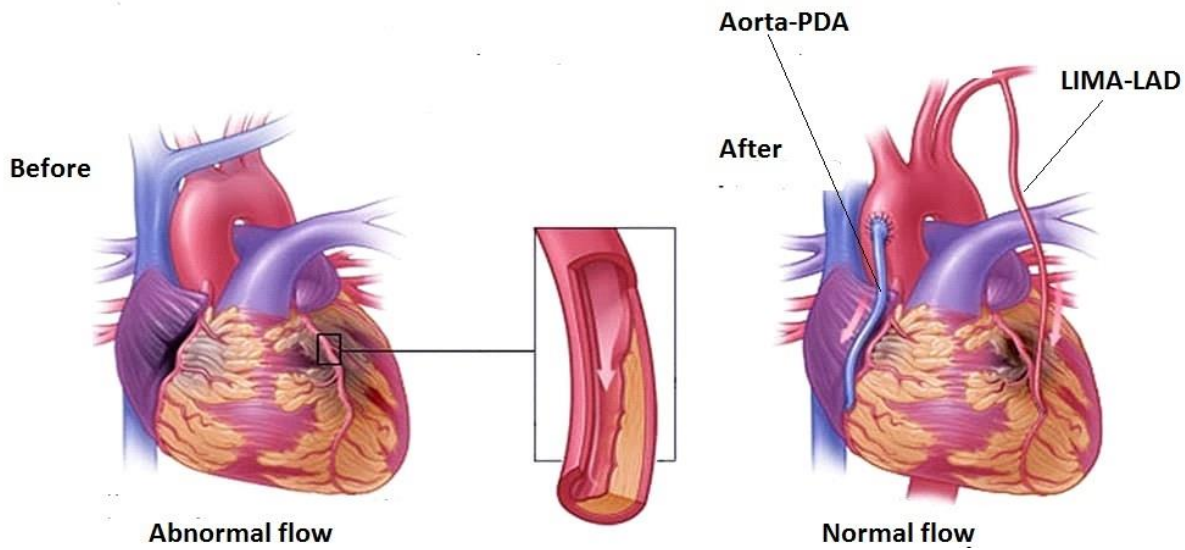


Figure 4. Schema of 2nd stage of correction - CABG: Arterial graft LIMA to LAD and venous graft aorta to PDA
CABG- coronary artery bypass surgery, LAD – left anterior descending artery, LIMA- left internal mammary artery, PDA – posterior descending artery

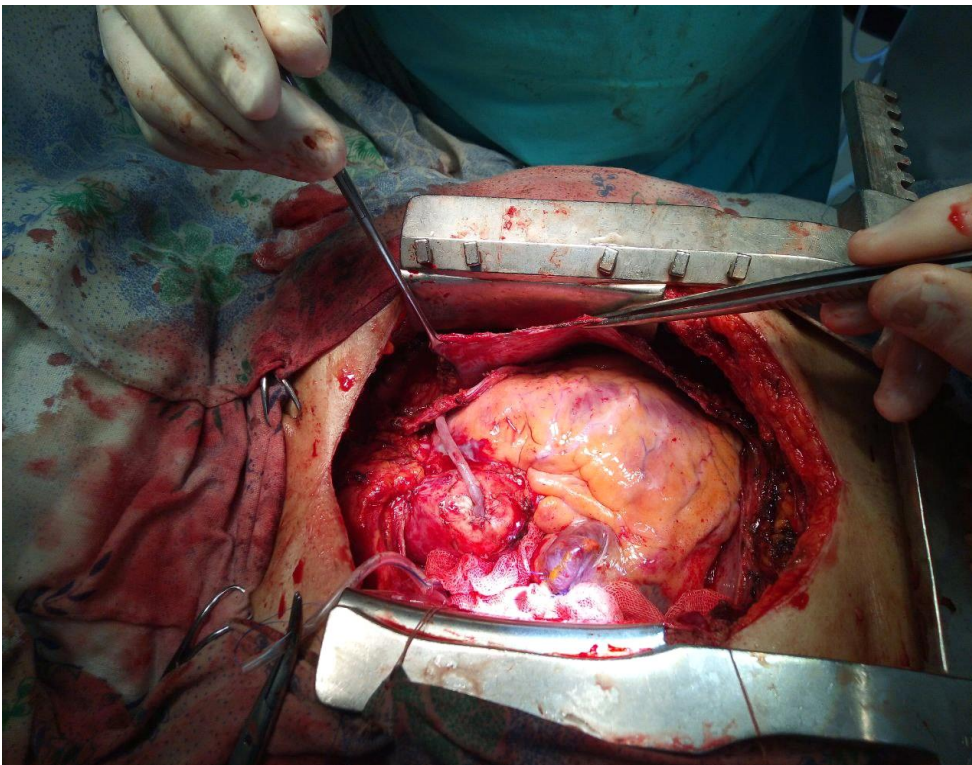


Figure 5. Intraoperative view of the 2nd stage of the operation - CABG: arterial - LIMA in the LAD and venous graft aorta to the PDA
CABG- coronary artery bypass surgery, LAD – left anterior descending artery, LIMA- left internal mammary artery, PDA – posterior descending artery

In the intensive care unit, complex therapy was carried out with correction of hemodynamic parameters, blood gases, fluid and electrolyte balance. After the restoration of consciousness, and stable functional indicators of all organs, systems, the patient was extubated. There were no surgical complications; anticoagulant and cardiac therapy, prevention of cardiorespiratory complications, and glucose correction were performed. On the 4th day after the operation, with stable indicators, the patient was transferred to the Department of Cardiac Surgery ward, where planned postoperative therapy continued. The wound healed without complications, at this stage there were no complications of the postoperative course.

In a relatively stable condition, the patient was discharged on the 10th day after with appropriate recommendations for continuing treatment at the place of residence.

Discussion

The presentation of this case of simultaneous surgical correction of a severe giant multiple neoplasm of the right heart, complicated by high pulmonary hypertension, obstruction of the tricuspid valve, as well as a combination with multiple critical coronary artery disease in the presence of type 2 diabetes mellitus, shows the possibility of adequate simultaneous correction of multicomponent heart pathologies.

Our patient was different from others diagnosed with a heart tumor - a myxoma with the presence of characteristic symptoms for coronary heart disease. Along with characteristic shortness of breath, weakness, palpitations, he noted chest pain, which was especially aggravated with a slight load. Male sex, age 68 years and the above complaints supported a preliminary view of a possible combination of heart tumor and other cardiovascular or pulmonary disease. Of course, it is appropriate to note here the data of the preliminary echocardiography performed in the outpatient clinic of our center, although the patient with these complaints was repeatedly treated at the place of residence. The lack of echocardiography during 4 years of symptoms, made it difficult to establish a combined pathology - heart neoplasm and coronary disease, as possible the neoplasm was not suspected at that time.

The importance of performing echocardiography in such patients has been proven by many studies (1, 2, 5, 8, 9).

However, a rare combination of cardiac myxoma with multivessel coronary vascular involvement is rarely reported in the literature. They emphasize the importance of accurate topical diagnosis and determination of the correct tactics of surgical treatment of this complex combined heart pathology (12-15).

The main guarantee of successful surgical treatment is the determination of the correct tactics for managing such patients: starting with the correct diagnosis, choosing the tactics of surgical correction, its adequate implementation and management of the postoperative period, with drug correction of concomitant diseases. Such cases of simultaneous correction of rare forms of complicated myxoma of large sizes and severe multivessel pathology of the coronary vessels in patients with diabetes mellitus are very rare (11, 13). The data of these authors and our case once again confirms the possibility of successful surgical treatment of several severe pathologies of the cardiovascular system (12, 14).

Conclusion

Our case demonstrates successful simultaneous surgical treatment of several severe pathologies of the cardiovascular system as double myxoma removal and coronary bypass surgery, with the right choice of surgical tactics and well-coordinated work of a team of cardiac surgeons, cardiac anesthesiologists, perfusionists, cardiologists, and reanimatologists.

Ethics: Informed consent was obtained from patient before all procedures

Peer-review: External and internal

Conflict of interest: None to declare

Authorship: Kh.A.A., A.A.M., Sh.T.U. equally contributed to case management and preparation of case report

Acknowledgment and funding: None to declare

References

1. Abdumajidov HA, Nazirova LA, Turgunov AI. Peculiarities of diagnostics, clinical examination and surgical treatment of cardiac myxomas. Toolkit. Tashkent 2016: 40 p.
2. Bockeria LA, Malashenkov AI, Kavsadze VE, Serov RA. Cardiooncology. Moscow: NTSSSH named after A.N. Bakulev RAMS: 2003. 254p.

3. Ikramov AI, Aliev ShM, Juraeva NM, Pulatov LA. MSCT angiography in the diagnosis of primary heart tumors. Proceedings of the Russian Congress of Cardiovascular Surgeons. Moscow. 2015, p. 32
4. Lugovsky MK. Myxomas of the heart: results of surgical treatment and clinical and morphological characteristics. Dissertation (DSC in Med 14.01.26) - Moscow: FGBU National Research Center for Transplantology and Artificial Organs named after Academician V. I. Shumakov of the Ministry of Health of the Russian Federation; 2017. 148 p.
5. Petrovsky BV, Konstantinov BA, Nechaenko MA. Primary tumors of the heart. Moscow; Medicine: 1997. 152 p.
6. Prikhodko VP, Nuzhdin MD, Primary heart tumors: history of development, modern principles and methods of surgical treatment. Circ Pathol Cardiac Surg 2011; 4: 64-70.
7. Revunenkov GV, Petrenets TN. An integrated approach to assessing the severity of hemodynamic disorders of the cardiovascular system in patients with rhabdomyomas ????? 2017; DOI: 10.15690/pf.v14i3.1745.
8. Ushakov AV, Zakharyan EA, Rizk GE. Myxomas of the heart: a modern view on the problem. Ukrainian J Cardiol 2013; 2; ???.
9. Zuet CK. Clinic, diagnosis and surgical treatment of left atrial myxoma. Abstract of the thesis (cand. med. Sci); Moscow 1980. 22p.
10. Yin L, He D, Shen H et al. Surgical treatment of cardiac tumors: a 5-year experience from a single cardiac center. J Thoracic Dis ??; ???: ??? -??. doi: 10.21037/jtd.2016.03.87
11. Mendel T, Gutkowska J, Rywik T, Zielinski T. Lateral medullary infarction due to left atrial myxoma--a case report. Neurol Neurochir Pol 2002; 36: 1001-6.
12. Sachithanandan A, Badmanaban B, McEneaney D, MacGowan SW. Left atrial myxoma presenting with acute myocardial infarction. Eur J Cardiothorac Surg 2002; 21: 543.
13. Tamura K, Nakahara H, Furukawa H, Watanabe M. Angina pectoris with a left atrial myxoma; report of a case. Kyobu Geka 2002; 55: 1142-4.
14. Toth C, Lengyel M. Images in cardiology: acute myocardial infarction as first manifestation of left atrial myxoma. Acta Cardiol 2002; 57: 365-6.