

Quiz -Imaging

Quiz: A round cyst-like structure in the right atrium

Case

A 43-year-old woman with a history of severe COVID infection and 6-week treatment in the intensive care unit (2 years ago) visited her family doctor complaining on nonspecific chest pain and palpitations. On 12-lead electrocardiogram, a few premature atrial contractions were recorded. Doctor recommended to perform an echocardiography

(echo). During the echo-examination normal cardiac chambers with good contractility and normal structure and function of valves were visualized. But from the modified apical right ventricular inflow view a round cyst-like structure was revealed in the right atrium not entering the right ventricle but partially obstructing the right ventricular inflow tract (Fig. 1).

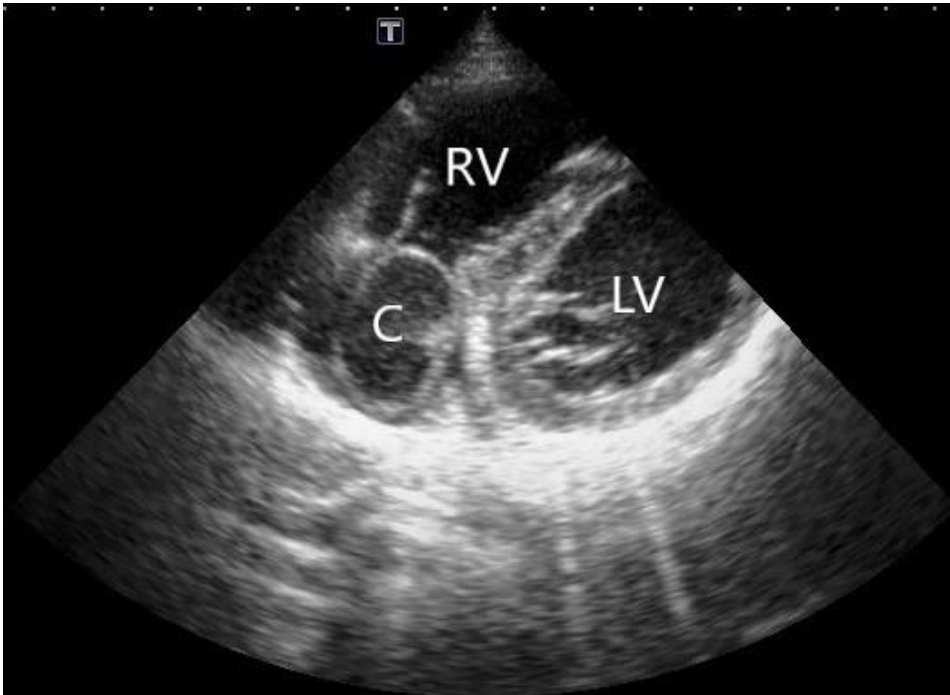


Figure 1. Echocardiographic image. The modified apical right ventricular inflow view

What this cyst-like structure could be?

1. Cardiac blood cyst.
2. Atrial septal aneurysm protruding from the left atrium into the right atrium.
3. Cardiac echinococcus cyst.
4. Foreign body (balloon) accidentally left in the right atrium during treatment in the intensive care unit.

Yuriy Ivaniv, Natalia Lozynska
Diagnostic Radiology Department, Danylo Halytsky
Medical University, Lviv, Ukraine

Ethics: Informed consent was obtained from patient for procedures

Peer-review: Internal

Conflict of interest: None to declare

Authorship: Y.I. and N.L. equally contributed to manuscript preparation

Acknowledgment and Funding: None to declare

Address for Correspondence: Yuriy Ivaniv, Diagnostic Radiology Department, Danylo Halytsky Medical University, Lviv, Ukraine

Email: yivaniv@gmail.com

ORCID: 0000-0002-2153-9262

Received: 21.01.2024 **Accepted:** 21.01.2024

Copyright ©2024 Heart, Vessels and Transplantation

DOI: 10.24969/hvt.2023.457