

Letter to the Editor

Comment on “Left ventricular perforation by a chest tube: Case report and review of complications”. Mind the left ventricle posterolateral wall please!

We read with interest a case report presented by Rojel Martínez et al. in the recent *Heart, Vessels and Transplantation* issue (1). In their article, authors described a patient with left pleural effusion who required the insertion of a chest drain. The drain was placed within the borders of the “safety triangle” but the tip of the catheter entered the left ventricle and reached the left atrium. Suspected by the blood output and confirmed on the computed tomography (CT), this complication required a thoracotomy with the removal of the drain and the repair of the ventricle wall damage.

Rojel Martínez et al. (1) discussed measures to prevent this lethal complication. Among them are: 1) safe chest wall area for the drain entrance; 2) secure insertion technique; 3) pre-procedural and intra-procedural imaging and 4) drain diameter selection. All these undoubtedly have the potential to reduce the risks of complications significantly. However, we believe it is essential to consider the spatial anatomy of the left ventricle to make the discussion more comprehensive.

The tradition to call the heart parts as “left” and “right” came from the most ancient times. Hippocrates in the 4th century B.C. has accepted this pattern already. He wrote in his treatise *The Heart*:

"The heart ... contains in one circumference two separate cavities (ventricles)...: the one on the right side lies face downwards, fitting closely against the other. By “right” I mean of course the right of the left side, since it is on the left side that the whole heart has its seat...The other cavity lies somewhat lower, and extends towards the line of the left nipple..." (2).

The concept of cardiac left-right laterization became generally accepted and remained unchallenged until the recent times. However, the introduction of digital three-dimensional reconstructions of live CT/

magnetic resonance imaging (MRI) obtained results that urged to conduct some revisions (3).

We performed three-dimensional reconstructions of the heart and chest in two patients using the 3D-Slicer (4). The images are presented in Figures 1 and 2. Figure 1 shows CT reconstructions of the normal heart. Right heart chambers are blue and left heart chambers are red. Observing the heart in Figure 1a from the front, in Figure 1b from the left side, one comes to a conclusion that the right ventricle is located anteriorly, while the left ventricle is positioned posteriorly. The former is displaced somewhat to the right and the latter to the left because the apex of the heart is not pointing to the left strictly but more to the left-anteriorly.

In Figures 1c-d the heart is placed into the chest. Observing the heart-chest complex in Figure 1c from the posterolateral and in Figure 1d from the posterior and above, it is possible to appreciate the distance from the “safe triangle” to the posterolateral wall of the left ventricle.

Do such clarifications provide with any practical values? The following example may give a clue.

In Figure 2, magnetic resonance imaging (MRI) reconstructions of the heart with dilated cardiomyopathy and severe enlargement of the left ventricle are given. Inspections from the front in Figure 2a and from the side in Figure 2b indicate that the left ventricle posterolateral wall is displaced not that impressively to the left but mostly to the back. Observing the heart-chest complex in Figure 2c suggests the distance from the “safe triangle” of the chest wall is reduced as compared to the normal. Therefore, in this patient there would be less free space for the drain passage than one might expect if thinking of the left ventricle as the exclusively lateral dislocation.

Address for Correspondence: Vitaliy Petrov, Department of Surgery and Transplantology, Danylo Halytsky National Medical University, Lviv, Ukraine

Email : vtly.12@gmail.com **ORCID:** 0000-0002-2205-5403

Received: 31.01.2024 **Accepted:** 31.01.2024

Copyright ©2024 Heart, Vessels and Transplantation

doi: 10.24969/hvt.2023.461

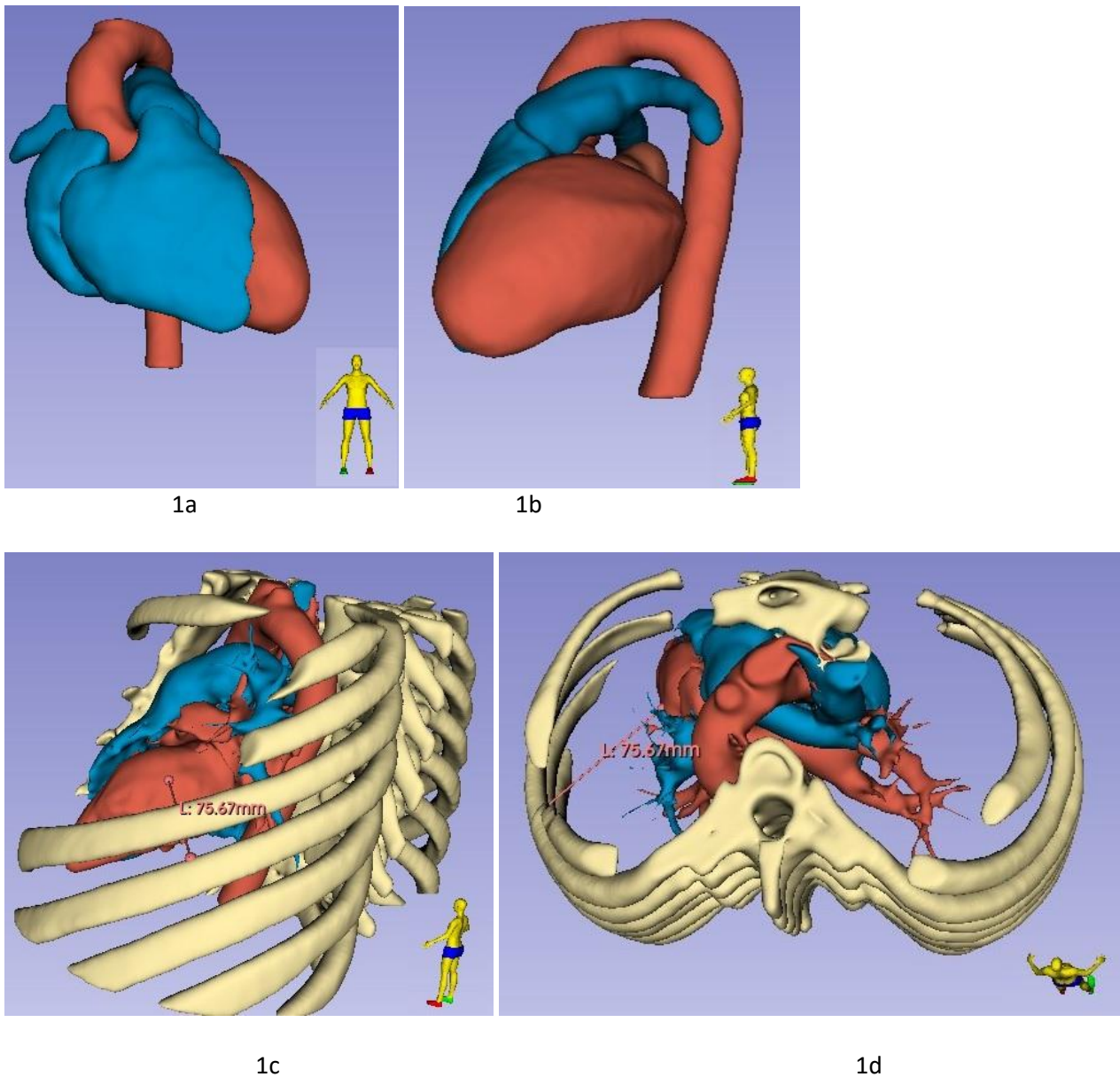


Figure 1. Computed tomography reconstruction of the heart (see explanations in the text)

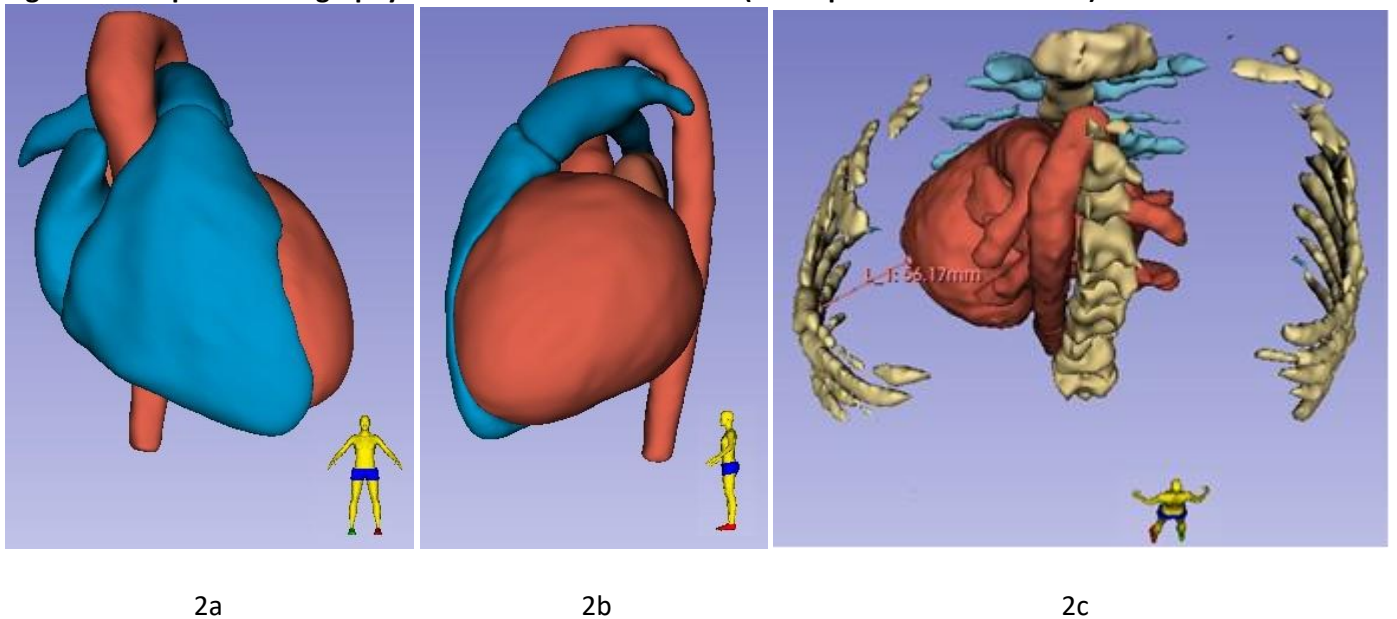


Figure 2. Magnetic resonance imaging reconstruction of the heart (see explanations in the text)

Calling the anatomically posterior ventricle “left” we must nevertheless keep in mind its expansion steals both left and posterior space, jeopardizing the potential trajectory of the stylet. Even if the drain entrance into the chest is safe, the enlarged ventricle will be prone to meet the needle inside the cavity.

Vitaliy Petrov

Department of Surgery and Transplantology
Danylo Halytsky National Medical University, Lviv,
Ukraine

Peer-review: Internal

Conflict of interest: None to declare

Authorship: V.P.

Acknowledgment and Funding: None to declare

References

1. Rojel-Martinez U, Reatiga-Vega PA, Marquez-Maldonado FM, Cordova-Fierro A, Bozada-Nolasco K. Left ventricular perforation by a chest tube: Case report and review of complications. *Heart, Vessels and Transplantation*. 2024; 8: doi: 10.24969/HVT.2024.456
2. Lloyd G, editor. *Hippocratic Writings*. Penguin Classics; 1984.
3. Mori S, Tretter JT, Spicer DE, Bolender DL, Anderson RH. What is the real cardiac anatomy? *Clin Anat* (New York, N.Y.) 2019; 32: 288–309. doi: 10.1002/CA.23340
4. Fedorov A, Beichel R, Kalpathy-Cramer J, Finet J, Fillion-Robin JC, Pujol S, et al. 3D Slicer as an image computing platform for the quantitative imaging network. *Magn Reson Imaging* 2012; 30: 1323–41. doi: 10.1016/j.mri.2012.05.001