

# Experience of treatment of newborns with gastroschisis in the conditions of the national center for maternal and child health care

Tatyana A. Akmentieva<sup>1\*</sup>, Kamchibek A. Uzakbaev<sup>2</sup>, Natalia .F. Gagloeva<sup>1</sup>

National Center for Maternal and Child Health, Bishkek, Kyrgyzstan

Salymbekov University, Bishkek, Kyrgyzstan

## Abstract

**Objective:** The objective of the study was to evaluate effectiveness of different surgical methods and the results of treatment of newborns with gastroschisis in the National Center for Maternal and Child Health (Bishkek), based on the data of the intensive care unit of newborns with surgical pathology.

**Methods:** From 2016 to 2023, 56 newborns with gastroschisis were admitted to the intensive care unit of newborns with surgical pathology on the basis of the National Center for Maternal and Childhood Care in Bishkek.

**Results:** All 56 (100%) neonates were with intrauterine developmental delay. They were also hospitalized in the neonatal intensive care unit when gastroschisis was diagnosed. All children underwent preoperative preparation, which included correction of metabolic, hemodynamic disorders, normalization of body temperature and adequate diuresis. The algorithm of diagnostic examinations included clinical and laboratory methods, ultrasonography and ultrasonography of internal organs, cardiac ultrasonography, bacterial blood culture, and high cleansing enemas with warm physiological solution to reduce the volume of intestinal loops and maximize their immersion in the abdominal cavity. Forty-six (82%) newborns underwent primary plasty of anterior abdominal wall defect and 10 (17.8%) newborns - two-stage plasty of the anterior abdominal wall. Postoperative mortality was 22 (39.2%).

**Conclusion:** Analyzing the existing methods of surgical correction to date, none of them has absolute effectiveness in the treatment of gastroschisis. Each of these methods has its advantages and disadvantages. There is a steady tendency to increase the number of radical operations performed in children with gastroschisis, which is associated with the improvement of methods of nursing newborns in the postoperative period.

**Key words:** Gastroschisis, developmental anomalies, newborns, diagnosis, siloplasty

(Heart Vessels Transplant 2024; 8: 463-8. doi: 10.24969/hvt.2024.515)

## Introduction

Studies in recent decades have shown that among congenital malformations of the anterior abdominal wall, one of the leading places is occupied by gastroschisis, a malformation of the anterior abdominal wall in which the abdominal organs are protruded through the paraumbilical defect of its soft tissues, usually located to the right of the normally formed umbilical cord. The incidence of this condition averages 1:5000, and is more than three times higher among mothers younger than 20 years of age. Chromosomal anomalies in gastroschisis are extremely rare. There is a tendency to increase the number of newborns with gastroschisis worldwide. Thus, this problem occupies an important place in the structure of surgically correctable congenital malformations (1).

The term "gastroschisis" was coined in 1894 by Italian pathologist Cesare Taruffi, who used it in his book *Storia della Teratologia* to define various congenital malformations in which the abdomen remains open at birth, although sporadic reports of this condition had been reported since 1557. In 1887, William P. Haug of West Virginia reported the first successful repositioning of the viscera and application of plaster strips. The child survived and appeared to have spontaneous closure of the defect by the age of 5 weeks. This case represents the first evidence of the resilience of an infant with gastroschisis, and this observation has been confirmed in the medical literature since that time (7).

The term gastroschisis is derived from the Greek words "gaster" for "stomach" and "schisis" for "slit" and has been used to refer to all defects of the anterior abdominal wall (2).

**Address for Correspondence:** Tatyana .A. Akmentieva, National Center for Maternal and Child Health, Bishkek, Kyrgyzstan

**E-mail:** akmen-ta@yandex.ru

**ORCID:** Tatyana A. Akmentieva – 0009-0000-4043-9278

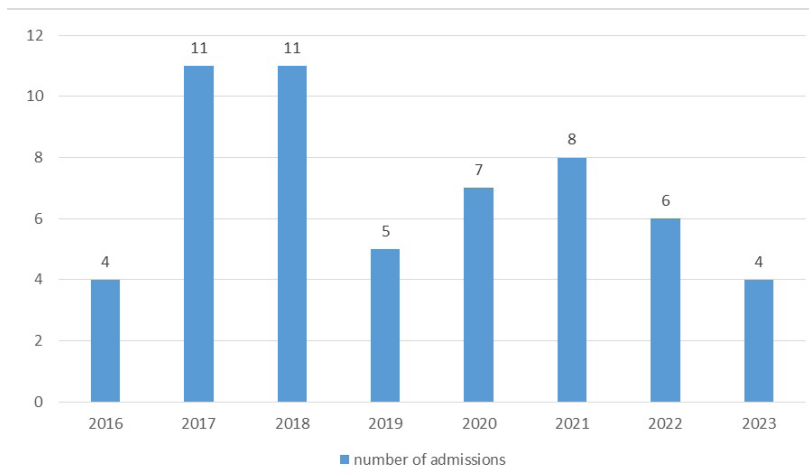
**Citation:** Akmentieva TA, Uzakbaev KA, Gagloeva NF. Experience of treatment of newborns with gastroschisis in the conditions of the national center for maternal and child health care. *Heart Vessels Transplant* 2024; 8: 463-8. doi: 10.24969/hvt.2024.515

**Received:** 01.05.2024 **Revised:** 06.08.2024 **Accepted:** 07.08.2024

**Copyright** ©2024 Heart, Vessels and Transplantation

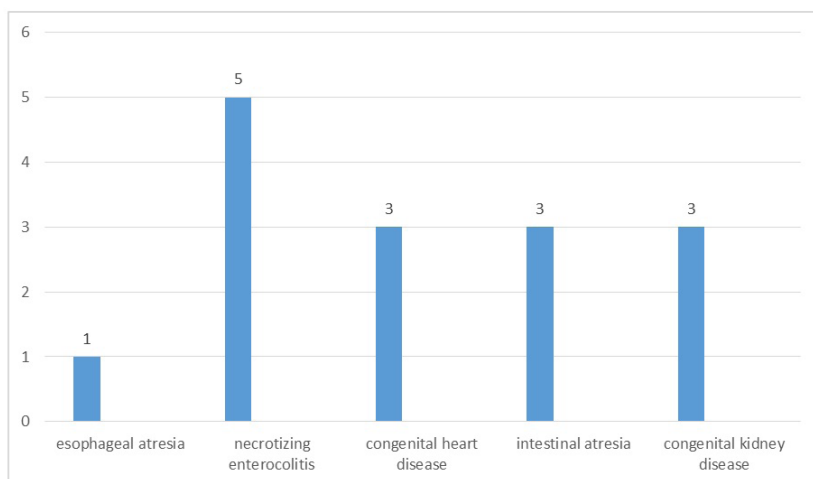
**Graphical abstract**

**Experience of treatment of newborns with gastroschisis in the conditions of the national center for maternal and child health care**



**Primary plasty of anterior abdominal wall defect - 46 (82%)**  
**Two-stage plasty of the anterior abdominal wall - 10 (17.8%)**  
**Postoperative mortality - 22 (39.2%)**

**Dynamics of admissions of newborns with gastroschisis**

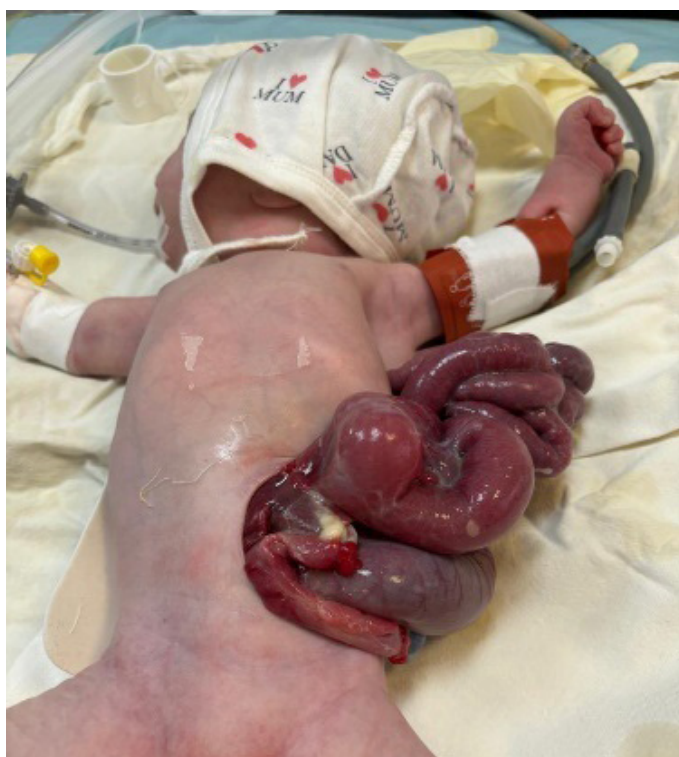

**Accompanying malformations in newborns with gastroschisis**

The severity of the condition of newborns with abdominal wall malformations depends on both the form of the malformation and the premorbid background (concomitant malformations, prematurity, immaturity, persistent intrauterine infections, sepsis).

Thus, the literature reports 67% postoperative mortality in gastroschisis in the group of children with associated malformations, while in isolated forms of gastroschisis the postoperative mortality is 19% (3). After birth, the newborn needs special care because of the open bowel (Fig. 1). The defect must be closed, which can be difficult if it is large and other abdominal organs are also herniated; however, the prognosis is usually good (8). To date, there are many methods of surgical treatment of the uncomplicated form of

this disease, which can be grouped into two groups: primary radical correction and staged immersion of the intestinal loops into the abdominal cavity with subsequent plasty of the abdominal wall. Each method has its advantages and disadvantages. The second category of surgeries is used in cases of pronounced viscer-abdominal disproportion and involves the creation of a temporary reservoir to accommodate the exerted organs (siloplasty), as well as artificial increase in the size of the child's abdominal cavity (4). Primary radical anterior abdominal wall grafting (PRAP ABWG) restores gastrointestinal function much faster and shortens treatment time significantly. If it is impossible to perform PRAP, alloplasty of the anterior abdominal wall using patches made of plastic materials or extracorporeal siloplasty bag is performed (5).



**Figure 1. Newborn with gastroschisis**

(The permission of parents was obtained)

The purpose of the study was to evaluate effectiveness of different surgical methods and the results of treatment of newborns with gastroschisis, based on the data of the neonatal intensive care unit with surgical pathology.

## Methods

### Study design and population

This was an observational retrospective study. From 2016 to 2023, 56 newborns with congenital malformation of the anterior abdominal wall - gastroschisis admitted to the neonatal intensive care unit with surgical pathology on the basis of the National Center for Maternal and Childhood Care in Bishkek were included in the study.

The informed consent parents or guardians of newborns for all procedures was obtained. The approval of Institutional Ethical Committee was not required for retrospective study.

We collected following variables as underlying pathology, type of surgery, complications and postoperative mortality.

### Surgery and perioperative examinations

All newborns were operated on in the first hours of life. They were also hospitalized in the neonatal intensive care unit

when gastroschisis was diagnosed. All children underwent preoperative preparation, which included correction of metabolic, hemodynamic disorders, normalization of body temperature and adequate diuresis. The algorithm of diagnostic examinations included clinical and laboratory methods, ultrasonography and ultrasonography of internal organs, cardiac ultrasonography, bacterial blood culture, and high cleansing enemas with warm physiological solution to reduce the volume of loops and maximize their immersion in the abdominal cavity. Preoperative preparation was carried out for several hours. The newborns received antibiotic therapy before bacterial blood culture and infusion therapy. Primary plasty of anterior abdominal wall defect or delayed anterior abdominal wall plasty or two-stage plasty of the anterior abdominal wall were performed.

After surgical treatment, newborns continued to receive respiratory support, planned analgesia and antibacterial, post-syndromal therapy aimed at preventing the development and elimination of complications, restoring the motor and evacuatory function of the gastrointestinal tract.

After surgery, parenteral nutrition was continued on average up to 30 days, which is associated with prolonged pseudoobstruction syndrome and impaired intestinal motility.

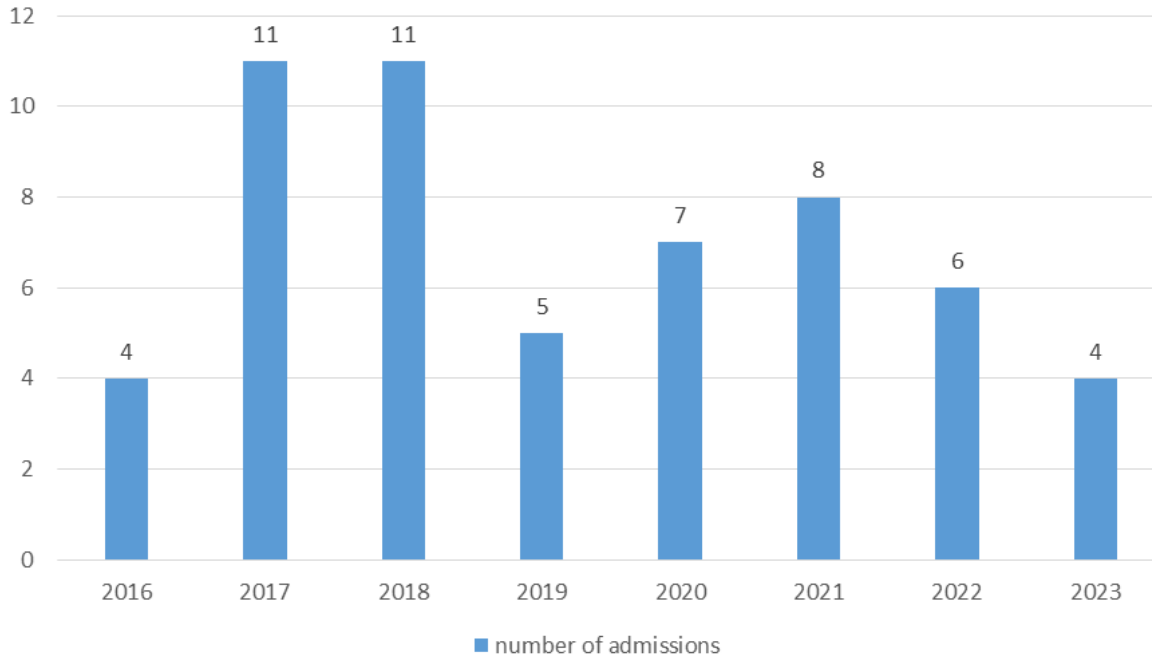
### Statistical analysis

We used descriptive statistics and data are presented as numbers and percentages.

### Results

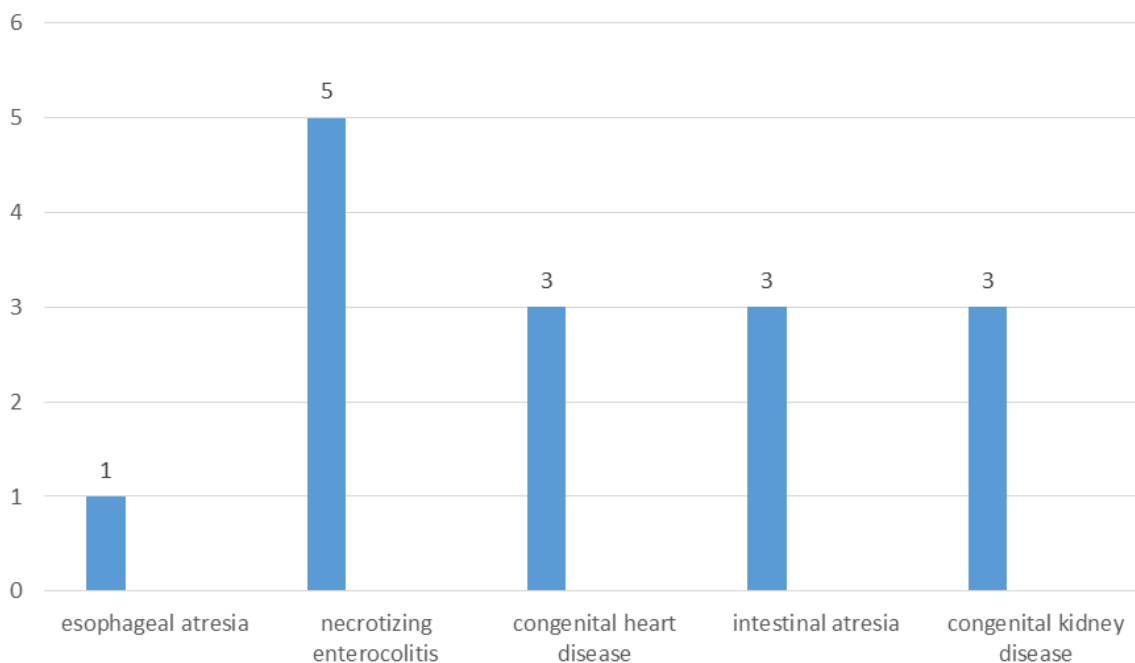
As can be seen from Figure 1, the highest number of admitted gastroschisis cases were in 2017 and 2018 and the lowest

number in 2006 and 2023. All 56 (100%) newborns had intrauterine developmental delay. In 80%, the diagnosis of gastroschisis antenatally was made late in gestation.



Overall, 26.7% (15) of children had combined malformations (Fig. 2). In 1 child gastroschisis was combined with esophageal atresia and death occurred in the early postoperative period. In 5 children gastroschisis was combined with necrotizing

enterocolitis of IIB - IIIB degree with intestinal perforation and spilled peritonitis. In 6 newborns, gastroschisis was combined with multiple malformations: genitourinary malformations, congenital heart disease and intestinal atresia.



**Figure 2. Combined malformations**

As can be seen from Table 1, primary plasty of the anterior abdominal wall defect with one-stage organ immersion was performed in 46 infants (82%). If primary radical plasty was not possible, delayed anterior abdominal wall plasty was

performed. At the same time, the method of extracorporeal siloplasty bag was used in 10 children (17.8%).

Number of newborns	Primary plasty of anterior abdominal wall defect	Two-stage plasty of the anterior abdominal wall
56 (100%)	46 (82%)	10 (17.8%)

In patients with primary plasty of the anterior abdominal wall, there was a decrease in septic processes in newborns, faster recovery of the gastrointestinal passage and it was possible to start earlier enteral loading. Primary closure is successful in 70% of cases.

In the postoperative period, 22 (39.2%) newborns died after surgery. The lethality of children with gastroschisis in the early postoperative period was due to multi-organ failure on the background of a sharp increase in intra-abdominal pressure during immersion of organs in the abdominal cavity with viscerο-abdominal disproportion, development of septic process and concomitant perinatal pathology.

### Discussion

In our study, 56 patients with gastroschisis underwent primary plasty or two-stage plasty of abdominal wall.

Primary closure was successful in 70% of cases and less complications were seen.

The preferred method of surgical closure continues to be a matter of debate among pediatric surgeons, while postoperative treatment is aimed at accelerating the onset and progression of enteral nutrition and minimizing complications (9). Surgical treatment can be one-stage or two-stage, depending on the degree of abdominal cavity development and the severity of viscerο-abdominal disproportion syndrome. Maximum immersion can lead to a formidable complication in the form of increased intra-abdominal pressure and compression of the inferior vena cava and renal vessels, which leads to the development of multi-organ failure (6).

Our study demonstrated mortality of 39.2% after surgery, where majority (82%) of our patients underwent primary plasty of abdominal wall and 17.8% underwent two-stage plasty. Our data on mortality is lower than reported previously in group of patients with congenital comorbidities (67%) and higher than in patients with isolated gastroschisis (3, 8). This can be explained by that one-fourth (26.7%) of our patients had concomitant congenital malformations.

In addition, lethality depends largely on the correct preoperative preparation, which should start from the

maternity hospital, but to date, this scheme remains not fully worked out with the maternity hospitals of the Republic of Kyrgyzstan.

### Study limitations

The main study limitations are small number of patients and its descriptive nature. Further comparative study of outcomes is needed.

Conclusion: Analyzing the existing methods of surgical correction to date, none of them has absolute effectiveness in the treatment of gastroschisis. Each of these methods has its advantages and disadvantages. However, with the use of primary plasty of the anterior abdominal wall there was a decrease in septic processes in newborns, faster recovery of the gastrointestinal passage and earlier it was possible to start enteral loading. Primary closure is successful in 70% of cases. Mortality rate was comparable to previous studies and depended on associated congenital malformations.

There is a steady tendency to increase the number of radical operations performed in children with gastroschisis, which is associated with the improvement of methods of nursing newborns in the postoperative period.

**Ethics:** The informed consent parents or guardians of newborns for all procedure was obtained. The approval of Institutional Ethical Committee was not required for retrospective study.

**Peer-review:** External and internal

**Conflict of interest:** None to declare

**Authorship:** T.A.A., K.A.U., and N.F.G. equally contributed to the study and manuscript preparation and fulfilled authorship criteria.

**Acknowledgements and funding:** None to declare

**Statement on A.I.-assisted technologies use:** We declare that we did not use AI-assisted technologies in preparation of this manuscript

**Availability of data and material:** For collaboration requests contact authors in frame of ethics.

## References

1. Teplyakova OV. Optimization of intensive therapy treatment tactics of newborns with gastroschisis. Diss. Cand. med.nauk. M.,2016.-122c.
2. Opitz, J.M. Gastroschisis. *Am J Med Genet* 2007; 143A: 635–8.
3. Chamathanova EM, Kucherov Yul, Podurovskaya YuL, Dorofeeva EI, Jirkova YuV. Gastroschisis: problems, initial experience, algorithm of therapy tactics. *Obstr Gynecol* 2011; 1: 36-41.
4. Shifdakov IH, Kalniyazov BM. Two-stage treatment of gastroschisis using alternative method of siloplasty. *Russ Vestn Pediatr Surg Anseshesiol Reanim* 2018; 8: 94-8 doi: 10.30946/2219-4061-2018-8-2-94-98
5. Bisaliev BH, Tsap NA. Experience of treatment of patients with gastroschisis. *Vestn Hirurg II Grekova* 2015; 174: 46-51. doi: 10.24884/0042-4625-2015-174-6-46-51
6. Pavlova SY, Savvina VA, VArfolomeeva AP, Nikolaev VN. Treatment of gastroschisis. *Vestn Severo-Vost Fed Univ NK Amosov* 2019; 2: 57-62.
7. Mattei P. *Fundamentals of Pediatric Surgery*. Springer Science+Business Media, LLC 2011; pp. 353 doi 10.1007/978-1-4419-6643-8\_45
8. Stephenson CD, Lockwood CJ, MacKenzie AP. *Gastroschisis /uptodate*: Oct 13, 2022.
9. Skarsgard ED. Management of gastroschisis. *Curr Opin Pediatr* 2016; 28: 363-9. doi: 10.1097/MOP.0000000000000336