

Quiz: Electrocardiogram

Mykhaylo Sorokivskyy

Danilo Hlacky University, Lviv, Ukraine

Female, 44 years, complains on feeling of palpitations and interruptions in the heart work. Several months ago patient suffered from acute myocarditis. Fragment of electrocardiogram (ECG) was recorded using 12 leads Holter monitor during sleep time, speed of the recording – 25 mm/s (Fig. 1).

The best way to describe these ECG changes is:

- A) Supraventricular tachycardia
- B) Sinus rhythm with first-degree atrioventricular block
- C) Accelerated junctional rhythm
- D) Atrial flutter with 2:1 conduction

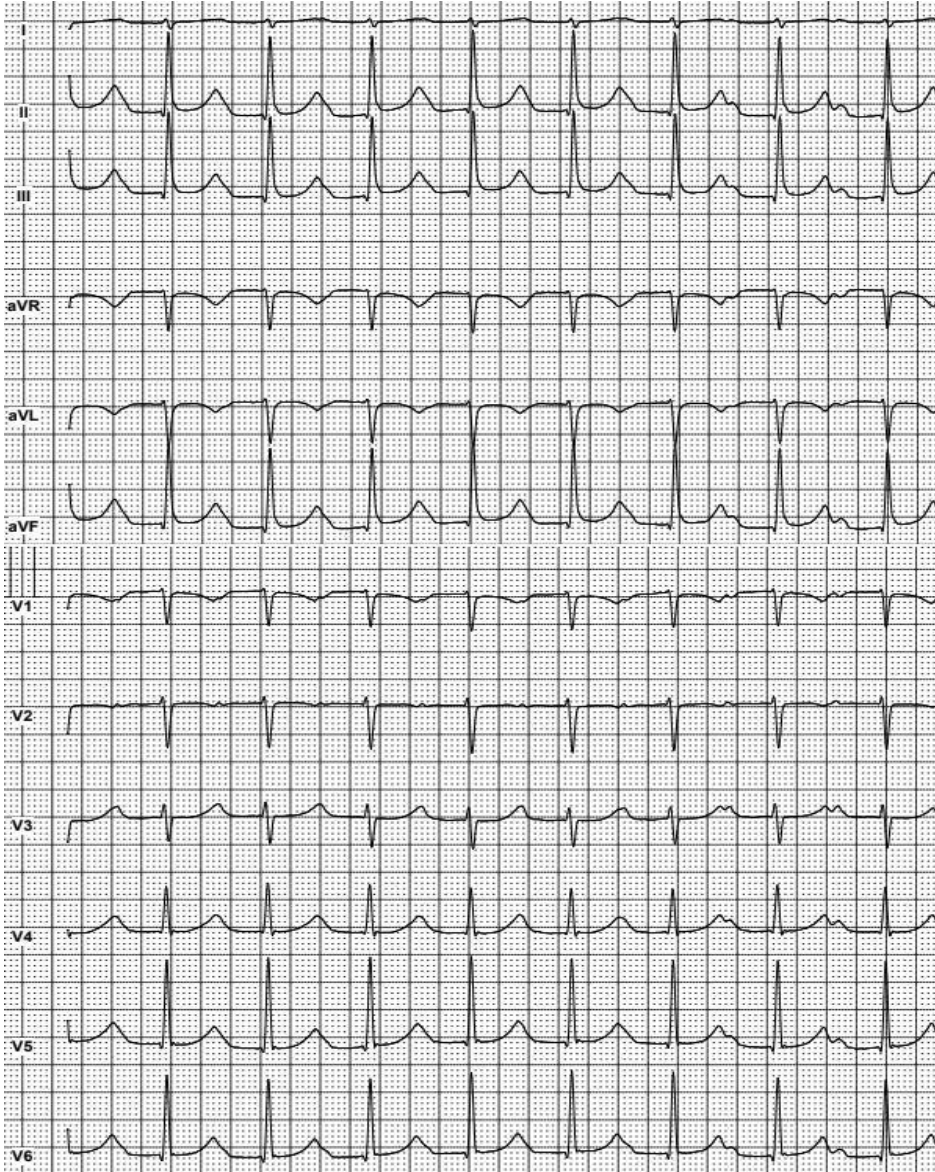


Figure 1. A 12-lead Holter monitoring fragment.

Address for Correspondence: Mykhaylo Sorokivskyy, Danilo Hlacky University, Lviv, Ukraine Email: msorokivskyy1@gmail.com

Received: 07.04.2018 **Accepted:** 08.04.2018 **doi:** 10.24969/hvt.2018.59

Copyright©2018 Heart Vessels and Transplantation